

UDC: 616.681-005.4-02:616.34-007.43-031:611.957]-07-053.31  
DOI: 10.24061/2413-4260. XIV.3.53.2024.23

## ACUTE TESTICULAR ISCHEMIA CAUSED BY INGUINAL HERNIATION WITH INCARCERATED LOOP OF SIGMOID COLON IN NEWBORN.

A. Fedoruc, A. Pisarenco, I. Revenco

Mother and Child Institute, National Scientific-Practical Center of Pediatric Surgery «Natalia Gheorghiu», State University of Medicine and Pharmacy «Nicolae Testemitanu» (Kishinev, Republic of Moldova)

### Summary

The authors report a clinical case of a 14-day-old newborn with a left inguinal hernia with incarceration of the sigmoid loop associated with testicular ischemia, a clinical situation that posed some problems of differential diagnosis. The mother of the child was referred to the emergency department. Objective examination revealed hyperemia and edema of the left hemiscrotum, and on palpation there was a hard, irreducible, painful swelling. The child was urgently taken to surgery. On re-examination an incarcerated hernia was found with a viable sigmoid loop with moderate edematous changes. The testis showed obvious ischemic changes. With difficulty, the sigmoid colon was reduced into the abdominal cavity, after observing the restoration of vascularization of the preserved testis. The postoperative result was positive and the child was discharged in satisfactory condition.

**Key words:** Incarcerated Hernia; Sigmoid Colon; Newborn.

The incarceration rate of inguinal hernias in children ranges from 3 to 16 %, with a higher incidence in infants. This can be explained by the smaller dimensions of the inguinal canal and the internal ring through which the herniated intestinal loops pass, which can easily become trapped, causing obstruction or later strangulation. One of the possible consequences of an incarcerated inguinal hernia in boys is testicular ischemia due to prolonged compression of the spermatic cord structures by the contents of the sac, with ipsilateral testicular atrophy. This complication is well described in the literature and occurs in 5-34 % of patients [1]. Testicular necrosis can be a serious consequence of inguinal hernia incarceration in children, leading to ipsilateral testicular loss [2].

Sigmoid colon as contents of inguinal hernia is a very rarely reported event in children [3]. We report a case of a child with a left-sided inguinal hernia with incarceration of the loop of the sigmoid colon associated with testicular ischemia, a clinical situation that posed some problems of differential diagnosis.

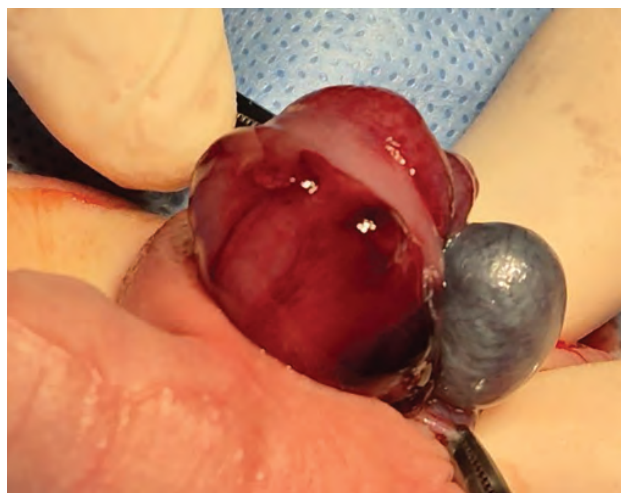A 14-day-old boy, born at term, weighing 3440 g, was presented to the emergency room with a hard, elastic, painful to palpation, purple colored hemiscrotal tegument in the left hemiscrotum, with a hard elastic formation in the left hemiscrotal region.

According to the mother, she noticed that the baby became restless and vomited about 24 hours before admission. During the diaper change, she noticed an enlargement of the left hemiscrotum, which later became hard and erythematous. The child was restless all night, so in the morning (09:00) the mother went to the emergency room of our institution. The history of inguinal hernia at birth was denied.

The objective examination revealed hyperemia and edema of the left hemiscrotum, and on palpation there was a hard, irreducible, painful swelling. The right testis was palpable at the scrotal root. The abdomen was soft and distended without signs of peritoneal irritation. The ultrasound examination revealed free fluid in the affected hemiscrotum, where a formation with faded contour and increased echogenicity was visualized, suggesting the diagnosis of testicular torsion. Although this combination of findings also suggested an incarcerated inguinal hernia,

the prophylactic diagnosis of acute scrotum and testicular torsion, favored by ultrasonography, was preferred.

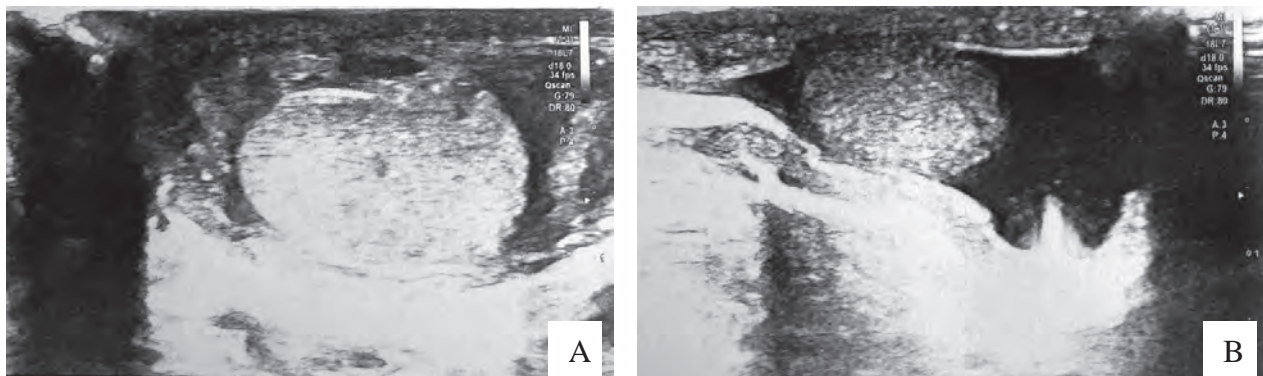
Urgently, about 28 hours after the onset of symptoms, the child was taken to surgery with an incision in the left hemiscrotal region. On exploration, a small amount of serous fluid was found. To avoid inadvertent injury to the bowel, the pouch was opened and a loop of sigmoid colon identified by haustration and mesocolon was found to be present. The sigmoid colon was viable with moderate edematous changes. The testis had obvious ischemic changes (Fig. 1). With gentle but difficult manipulation, it was possible to reduce the sigmoid colon into the peritoneal cavity after observing restoration of vascularization of the preserved testis.



**Fig. 1. Intraoperative appearance of the sigmoid colon and testis.**

An inguinal incision was then made through which the peritoneo-vaginal process was mobilized, ligated and excised. The operation was completed with drainage of the left hemiscrotum and restoration of the anatomic plane. The postoperative course was uneventful and the child was discharged in a satisfactory condition.

Postoperatively, more than 1 month after the operation, the parents have no complaints except for an insignificant increase in the volume of the right hemiscrotum.



**Fig. 2. Pcient V., 14-days-old. Post-operative ultrasound of the testes: A) the left testis; B) the right testis (explanations in text).**

On ultrasonographic examination of the scrotum, the left operated testicle was 13.0 x 7.0 x 9.0 mm, volume 0.5 cm<sup>3</sup>, clear, regular contour, relatively homogeneous parenchyma, medium echogenicity, normally vascularized (on power Doppler). Epididymis with normal sonographic appearance. Scrotal vas deferens with normal amount of free fluid. Pampiform venous plexuses are not dilated. Valsava maneuver negative (Fig. 2 A).

Right testis measuring 14.0 x 9.0 x 9.0 mm, volume 0.6 cm<sup>3</sup>, clear, regular contour, relatively homogeneous parenchyma, medium echogenicity, normally vascularized. Epididymis with normal sonographic appearance. Vaginal space of the scrotum with free fluid up to 7.0 mm thick with declivitous sediment with multiple hyperechogenic floating elements, the communicating hydrocele d-culum is established. The pampiform venous plexuses are not dilated (Fig. 2 B).

**Discussion.** Infants less than 6 months of age are comparatively more prone to testicular ischemia due to incarceration than older infants. It has been found that the propensity for testicular ischemia in infants is largely due to vascular structures that lack a rich network of testicular collateral vessels [4]. Testicular ischemia begins with herniation, which causes venous obstruction and increased pressure in a narrow and relatively rigid inguinal ring, with subsequent development of venous thrombosis, hemorrhage, and arterial insufficiency, resulting in unilateral congestive testicular infarction. In the case described, there was

a functional torsion of the testis, described in the literature as an incarcerated inguinal hernia, which resulted in an absence of vascular flow to the testis [5].

Testicular torsion with concomitant incarcerated inguinal hernia in children is rarely described in the literature [6]. While vascular torsion is the most common cause of testicular torsion, vascular compression as seen in an incarcerated or displaced inguinal hernia can lead to ischemia and infarction [7].

A communicating hydrocele is defined by complete patency of the vaginal process with a small opening at the internal ring allowing only fluid to flow. Infant hydrocele that communicates by history (fluctuating size) or examination (reducible fluid) is often repaired immediately after presentation. At the same time, there is evidence that hydrocele in infants may resolve spontaneously before the age of 18 months. According to the authors, there is a low risk of progression to herniation, which is rarely seen [8,9].

Therefore, the identification of an acute scrotum, especially in the neonatal period, can be challenging as the physical examination findings can be quite subtle. The surgeon must have a high index of clinical suspicion to make a correct diagnosis in cases of incarcerated inguinal hernia or testicular torsion to prevent the development of irreversible bowel changes and to preserve an inschemic testis. The possibility of testicular preservation in cases of advanced testicular ischemia caused by incarcerated inguinal hernia in infants should be considered.

#### References:

- Hou J, Feng W, Liu Q, Wang Y, Guo Z, Liu W. Can we preserve the necrotic testis caused by incarcerated inguinal hernia in infants under 3 months? *Pediatr Surg Int* [Internet]. 2023 [cited 2024 Jul 2];40(1):16. Available from: <https://link.springer.com/article/10.1007/s00383-023-05592-x> DOI: <https://doi.org/10.1007/s00383-023-05592-x>
- Dudek-Warchol T, Glug W, Kurek A, Bombinski P, Warchol S. Testicular necrosis secondary to incarcerated inguinal hernia in male infants. Own observation. *Dev Period Med*. 2018;22(1):65-70. DOI: <https://doi.org/10.34763/devperiodmed.20182201.6570>
- Roy AK, Ghildiyal JP. Impaction of feces in a loop of sigmoid colon: a rare cause of incarceration of inguinal hernia in children. *Int J Surg* [Internet]. 2008 [cited 2024 Jul 1];6(6): e7-e8. Available from: <https://www.sciencedirect.com/science/article/pii/S1743919106001865?via%3Dihub> DOI: <https://doi.org/10.1016/j.ijss.2006.08.005>
- Ozdamar MY, Karakus OZ. Ischemia caused by incarcerated inguinal hernia in infants: incidence, conservative treatment procedure, and follow-up. *Urol J*. 2017;14(4):4030-3.
- Orth R, Towbin A. Acute testicular ischemia caused by incarcerated inguinal hernia. *Pediatr Radiol*. 2012;42(2):196-200. DOI: <https://doi.org/10.1007/s00247-011-2210-4>
- Nisly D, Barnett S, Herzing K, Aranda A. Concurrent testicular torsion and acute incarcerated inguinal hernia in an adolescent boy. *BMJ Case Rep* [Internet]. 2018 [cited 2024 Jun 1];2028: bcr2018227087. Available from: <https://casereports.bmj.com/content/2018/bcr-2018-227087.long> DOI: <https://doi.org/10.1136/bcr-2018-227087>
- Taylor GM, Strachan C. Functional testicular torsion secondary to an incarcerated inguinal hernia in a 4-month old: complete recovery at 18-hours. *J Surg Case Rep* [Internet]. 2021 [cited 2024 Jun 8];2021(2): rjab022. Available from: <https://academic.oup.com/jscr/article-lookup/doi/10.1093/jscr/rjab022?login=false> DOI: <https://doi.org/10.1093/jscr/rjab022>

8. Koski ME, Makari JH, Adams MC, Thomas JC, Clark PE, Pope JC 4th, et al. Infant communicating hydroceles – do they need immediate repair or might some clinically resolve? *J Pediatr Surg.* 2010;45(3):590-3. DOI: <https://doi.org/10.1016/j.jpedsurg.2009.06.026>
9. Sabra TA, Abdelgawaad MS, Abdelmohsen SM, Abdelmohsen SM, Badawy A. Watchful waiting for communicating hydrocoele in infants. *Egypt Pediatr Assoc Gaz [Internet].* 2022 [cited 2024 Jul 7];70:50. Available from: [https://epag.springeropen.com/articles/10.1186/s43054-022-00142-x](https://epag.springeropen.com/articles/10.1186/s43054-022-00142-x#citeas) DOI: <https://doi.org/10.1186/s43054-022-00142-x>

## ГОСТРА ІШЕМІЯ ЯЄЧКА, СПРИЧИНЕНА ПАХВИННОЮ ГРИЖЕЮ З УЩЕМЛЕНОЮ ПЕТЛЕЮ СИГМОВИДНОЇ КИШКИ У НОВОНАРОДЖЕНОГО.

*А. Федорук, А. Писаренко, І. Ревенко*

Інститут матері та дитини, Національний науково-практичний центр дитячої хірургії «Наталія Георгіу»,  
Державний університет медицини і фармації «НіколаєТестеміцану»  
(м. Кишинів, Республіка Молдова)

### Резюме.

Автори описують клінічний випадок 14-денного новонародженого з лівою пахвинною грижею із защемленням петлі сигмовидної кишки, пов'язаною з ішемією яєчка, клінічну ситуацію, яка становила певні проблеми диференціальної діагностики. Мати дитини була скерована у відділення невідкладної допомоги. При об'єктивному обстеженні виявлено гіперемію та набряк лівої гемікротума, а при пальпації – тверду, незмінювану, болючу припухлість. Ургентно дитина була доставлена в хірургічне відділення. Під час ревізії виявлено ущемлену грижу, яка містила життєздатну петлю сигмовидної кишки з помірними набряковими змінами. Яєчко мало явні ішемічні зміни. З труднощами вдалося вправити сигмовидну кишку в черевну порожнину, спостерігаючи за відновленням васкуляризації яєчка, яка була збережена. Післяопераційний результат був позитивним, дитина виписана в задовільному стані.

**Ключові слова:** защемлена грижа; сигмоподібна кишка; новонароджений.

### Contact information:

**Ana Fedoruc** – PhD student (Doctoral School in Medical Sciences), resident doctor, National Scientific c- Practical Center for Pediatric Surgery «Natalia Gheorghiu», Mother and Child Institute (Kishinev, Republic of Moldova)

**e-mail:** [ann.cojocari.28@gmail.com](mailto:ann.cojocari.28@gmail.com)

**ORCID ID:** <https://orcid.org/0009-0003-6341-8228>

**Aliona Pisarenco** – MD, PhD, Pediatric Surgeon, National Scientific c- Practical Center for Pediatric Surgery «Natalia Gheorghiu», Mother and Child Institute (Kishinev, Republic of Moldova)

**e-mail:** [abirsan@mail.ru](mailto:abirsan@mail.ru)

**ORCID ID:** <https://orcid.org/0009-0009-0129-6839>

**Ina Revenco** – MD, PhD, Pediatric Surgeon, National Scientific c- Practical Center for Pediatric Surgery «Natalia Gheorghiu», Mother and Child Institute (Kishinev, Republic of Moldova)

**e-mail:** [ina.revenco@yahoo.com](mailto:ina.revenco@yahoo.com)

**ORCID ID:** <https://orcid.org/0000-0003-4976-0863>

### Контактна інформація:

**Федорук Ана** – аспірантка (Докторська школа медичних наук), лікар-ординатор, Національний науково-практичний центр дитячої хірургії «Наталія Георгіу», Інститут матері та дитини (м. Кишинів, Республіка Молдова)

**e-mail:** [ann.cojocari.28@gmail.com](mailto:ann.cojocari.28@gmail.com)

**ORCID ID:** <https://orcid.org/0009-0003-6341-8228>

**Писаренко Альона** – доктор медичних наук, дитячий хірург, Національний науково-практичний центр дитячої хірургії імені Наталії Георгіу, Інститут матері та дитини (м. Кишинів, Республіка Молдова)

**e-mail:** [abirsan@mail.ru](mailto:abirsan@mail.ru)

**ORCID ID:** <https://orcid.org/0009-0009-0129-6839>

**Ревенко Іна** – доктор медичних наук, дитячий хірург, Національний науково-практичний центр дитячої хірургії імені Наталії Георгіу, Інститут матері та дитини (м. Кишинів, Республіка Молдова)

**e-mail:** [ina.revenco@yahoo.com](mailto:ina.revenco@yahoo.com)

**ORCID ID:** <https://orcid.org/0000-0003-4976-0863>



Received for editorial office on 08/08/2024  
Signed for printing on 20/09/2024