

УДК: 616.36-002.951.21-036.1-089  
DOI: 10.24061/2413-4260. XIV.3.53.2024.10

## ASPECTS OF LIVER ECHINOCOCCOSIS SURGERY

*K. E. Rakhmanov*<sup>1</sup>, *J. P. Radjabov*<sup>1</sup>,  
*S. S. Davlatov*<sup>2</sup>, *B. Z. Khamdamov*<sup>2</sup>,  
*S. V. Yanchenko*<sup>2</sup>, *R. R. Navruzov*<sup>2</sup>

Samarkand State Medical University<sup>1</sup>  
(Samarkand, Uzbekistan),  
Bukhara State Medical Institute  
named after Abu Ali ibn Sino<sup>2</sup>  
(Bukhara, Uzbekistan)

### Summary

According to the WHO, «...at any given time, more than 1 million people worldwide are affected by echinococcosis...». Due to the lack of tendency to decrease the number of patients and the existence of endemic regions where the incidence rate varies from 1.2 to 9.0 per 100,000 population, this parasitic disease continues to be a serious medical and social problem. At the present stage, the diagnosis of echinococcosis does not present significant difficulties, mainly due to the emergence of non-invasive imaging methods, the informative value of the complex application of which reaches 95-100 %.

**Aim of the study.** Improving the treatment results of patients with liver echinococcosis.

**Research materials.** The study included 328 patients with liver echinococcosis admitted to the surgery department of the multidisciplinary clinic of the Samarkand State Medical University in the period from 2005 to 2023. Depending on the choice of treatment, the patients were divided into two groups: the comparison group consisted of 154 (46.9 %) patients treated from 2005 to 2012 and the main group included 174 (53.0 %) patients operated on from 2013 to 2023.

**Research results.** Compared with the comparison group, in the main group of patients, intraoperative complications decreased from 6.5 to 2.3 %, and complications in the early postoperative period from 18.2 to 5.2 %. In the late postoperative period, the recurrence of the disease decreased from 16.2 % to 3.6 %.

**Conclusions.** The introduction of improved surgical instruments into practice – a modified puncture needle, a «basket clamp» allowed to level the risk of seeding of surrounding tissues with embryonic elements. The introduction of a device for the purpose of identifying hidden biliary fistulas in the residual cavity after echinococcectomy from the liver reduced the number of bile leaks. With the introduction of a modified method for eliminating the residual cavity after echinococcectomy from the liver, the number of complications during surgery and in the early postoperative period was minimized.

**Key words:** Liver; Echinococcosis; Surgical Treatment.

### Relevance of the research

According to the WHO, «...at any given time, more than 1 million people worldwide are affected by echinococcosis...». Due to the lack of a decreasing trend in the number of patients and the existence of endemic regions where the incidence rate varies from 1.2 to 9.0 per 100,000 population, this parasitic disease continues to be a serious medical and social problem [1, 2, 3, 4, 5]. At the present stage, the diagnosis of echinococcosis does not present significant difficulties, mainly due to the emergence of non-invasive imaging methods, the informative value of which in complex application reaches 95-100 % [6, 7, 8].

However, lack of vigilance against echinococcosis contributes to late diagnosis and consequently to the increase of complicated forms of the disease [9, 10, 11, 12]. At the same time, treatment of echinococcosis of the abdominal cavity and thoracic organs is a serious surgical problem. Echinococcectomy with various variants of residual cavity elimination remains the most common surgical procedure, performed in the vast majority (90.6 %) of cases [13, 14]. As a consequence, the postoperative mortality rate of surgical patients averages 2.2 %, and postoperative recurrences are observed in 3-54 % of cases. In light of the above, the need to improve the known and develop new effective measures for the prevention and treatment of this formidable disease becomes obvious [15, 16, 17].

In the current literature, there is no consensus on the definition of the concept, causes, form and nature of recurrence, there is no consensus on the intraoperative antiparasitic treatment of the fibrous capsule wall, very little attention is paid to the role of residual cysts, and physicians remain cautious about the safety of antiparasitic drugs.

**Aim of the study.** Improving treatment outcomes for patients with hepatic echinococcosis.

**Research materials.** The study was based on 328 patients with hepatic echinococcosis who were admitted to the Department of Surgery of the Multidisciplinary Clinic of Samarkand State Medical University in the period from 2005 to 2023. Patients were divided into two groups according to the choice of treatment: the comparison group consisted of 154 (46.9 %) patients treated from 2005 to 2012, and the main group included 174 (53.0 %) patients operated on from 2013 to 2023. Of the 328 patients with liver echinococcosis, 275 (83.8 %) were first-time echinococcosis patients and 53 (16.2 %) were recurrent echinococcosis patients. Among them, 28 (52.8 %) patients had primary recurrence. Among 28 patients, 16 (57.1 %) patients underwent their first operation in our clinic in different years. 21 (39.6 %) patients had a history of two operations and 4 (7.5 %) patients had three operations in other hospitals.

According to the number of cysts, 246 (75.0 %) patients had solitary parasitic liver cysts. The characteristic localization of parasitic cysts was the right lobe of the liver – in 196 (79.7 %) patients. Echinococcal cysts were localized in the left hepatic lobe in 50 (20.3 %) patients. Multiple parasitic cysts of the liver were found in 82 (25.0 %) patients. Of these, 55 (67.1 %) patients had lesions in one lobe and 27 (32.9 %) patients had lesions in both lobes. In the right hepatic lobe, echinococcal cysts were predominantly localized in segments VII and VIII. The segmental localization of the cysts in the studied groups is shown in Table 1.

In the preoperative period, the size of the cysts was determined visually using ultrasound and CT scans of the liver and abdominal organs, as well as intraoperatively.

The size of the cysts in the liver varied from 2 to 30 cm in diameter and contained from a few milliliters to 3 liters of fluid, the majority (67.9 %) were patients with cysts of 5 to 10 cm. The fluid was transparent or colorless in 231 cases, light yellow, brown or turbid in 79 cases, and purulent in 18 cases.

The majority of patients were admitted to the hospital for a planned procedure. Therefore, the structure of lesions was dominated by patients with clinical stages I and II of parasitic life activity according to Melnikov's classification, which was 238 (72.6 %) people.

There were 90 (27.4 %) complicated cysts. We classified complications of liver echinococcosis as suppuration, rupture into the abdominal cavity and cystobiliary fistula formation (Table 1).

Table 1

Distribution of liver echinococcosis patients by type of complications

Defeat	patient group				total (n=328)	
	comparison group (n=154)		main group (n=174)		abc.	%
	abc.	%	abc.	%		
Uncomplicated echinococcosis	120	77,9	118	67,8	238	72,6
Complicated echinococcosis	34	22,1	56	32,2	90	27,4
Cysto-biliary fistulae	18	52,9	20	35,7	38	42,2
suppuration	11	32,3	17	30,3	28	31,1
suppuration + cysto-biliary fistulae	3	8,8	12	21,4	15	16,7
A breakthrough into the abdominal cavity	1	2,9	2	3,6	3	3,3
Mechanical jaundice	1	2,9	5	8,9	6	6,7

Cystobiliary fistulas prevailed in the structure of the listed complications – in 53 (58.9 %) patients. Festering of the cyst contents was observed in 28 (31.1 %) patients. Due to the cyst rupture into intrahepatic bile ducts, 6 (6,7 %) patients had mechanical jaundice. We did not observe a clinical case of mechanical jaundice due to biliary tract compression from outside by giant echinococcosis of the liver. In 3 (3.3 %) patients there was such a threatening complication as cyst rupture into the abdominal cavity.

In liver echinococcosis surgery, the so-called «local mini-access» has been widely used in our clinic since 2013, considering the individual characteristics of each patient.

In the main group, 106 (60.9 %) out of 174 patients underwent wide midline laparotomy and oblique subcostal access. 60 (34.5 %) patients underwent echinococcectomy from the local mini access. Laparoscopic echinococcectomy from the abdominal cavity was initially planned in 8 (4.6 %) patients. Of these, conversion was performed in 3 (37.5 %) cases for various reasons, i.e., echinococcectomy was performed via open mini-access in 2 patients and via wide access in 1 patient.

Based on the clinical course of the disease, we have developed and introduced into clinical practice an optimal therapeutic and tactical algorithm for the management of patients with echinococcosis of the abdominal cavity organs (Fig. 1).

We have developed a new sharp-pointed suction tip for a parasitic evacuation of echinococcal cyst contents. The tip is 1 cm in diameter with an inflatable balloon 2 cm from the

tip. After connecting the tip to a conventional aspirator, the cyst is punctured and inserted deeper into the cyst lumen above the inflatable balloon. (Fig.2).

One of the innovative solutions in patients of the main group was the use of a modified instrument «surgical clamp» (Certificate of official registration of utility model No. FAP 01499, Agency of Intellectual Property of the Republic of Uzbekistan «Surgical clamp») (fig. 3), consisting of 2 adhesive straight and concave blades, which converge and are able to grasp and hermetically hold together fragments and whole subsidiary or extrinsic cysts without the risk of their destruction and contamination of surrounding tissues.

We used a simple and safe method to detect hidden cystobiliary fistulas during surgery. The method of detecting hidden biliary fistula in the residual cavity after echinococcectomy from the liver was performed as follows. After echinococcectomy from the liver, in order to straighten the folds in the residual cavity, we introduced a special device developed by us (certificate of official registration of utility model No. FAP 02198, Intellectual Property Agency of the Republic of Uzbekistan «Method of detection of hidden fistulas in the residual cavity after echinococcectomy from the liver»), consisting of a handle 20 cm long, 1 cm in diameter, at the end of which there are plate blades of an elliptical shape, 12 cm long, 0.7 cm wide. When the handle is squeezed, the blades open, giving the working part of the device a spherical shape. (Fig. 4).

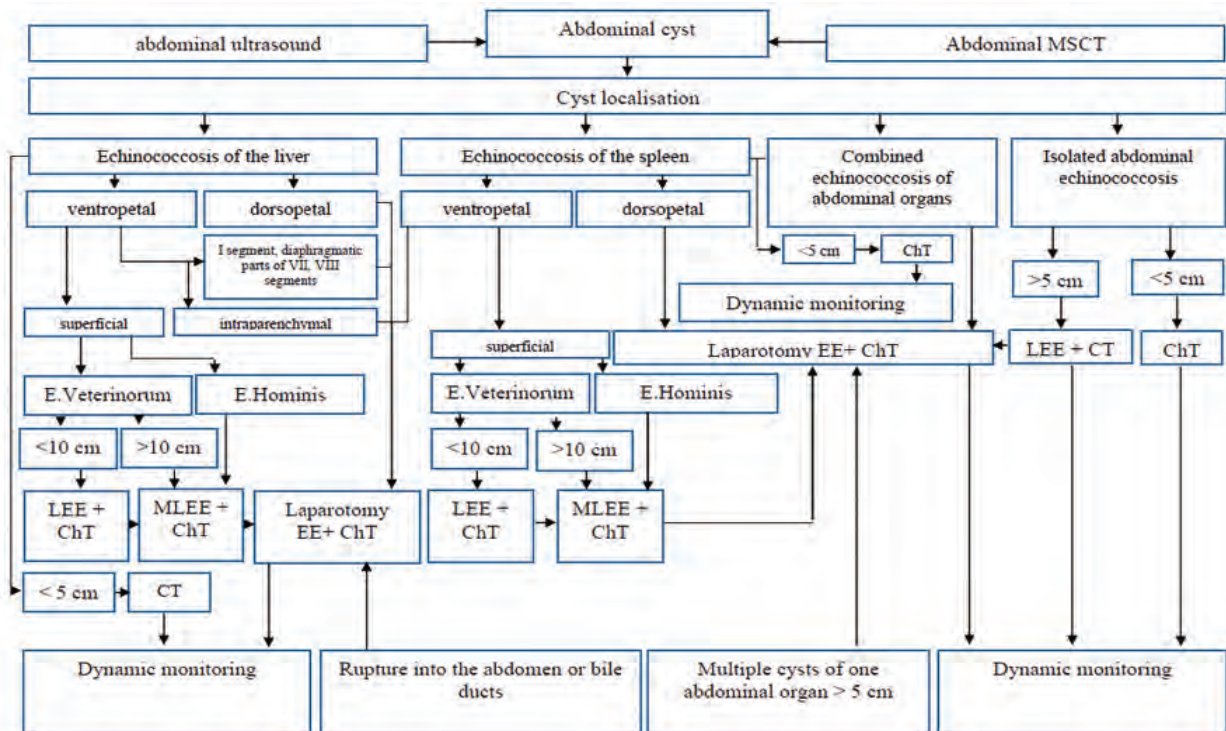


Fig. 1. Therapeutic and diagnostic algorithm of management of patients with echinococcosis of abdominal cavity organs

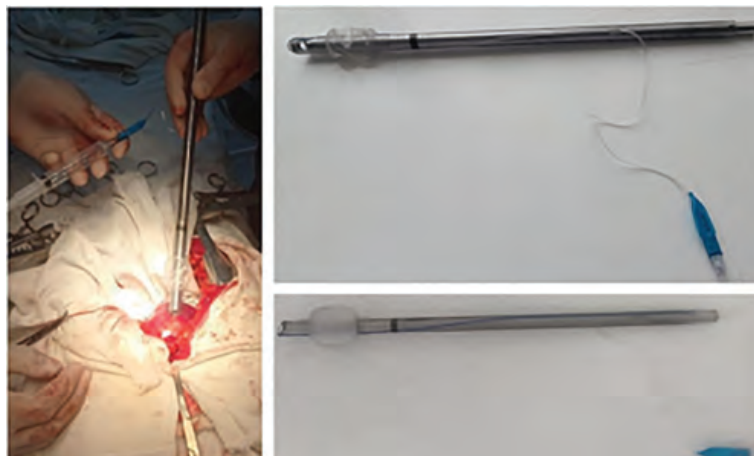


Fig. 2. Advanced puncture needle with balloon, balloon deflated and inflated



Fig. 3. «Basket clamp» – an instrument for echinococcectomy



A.

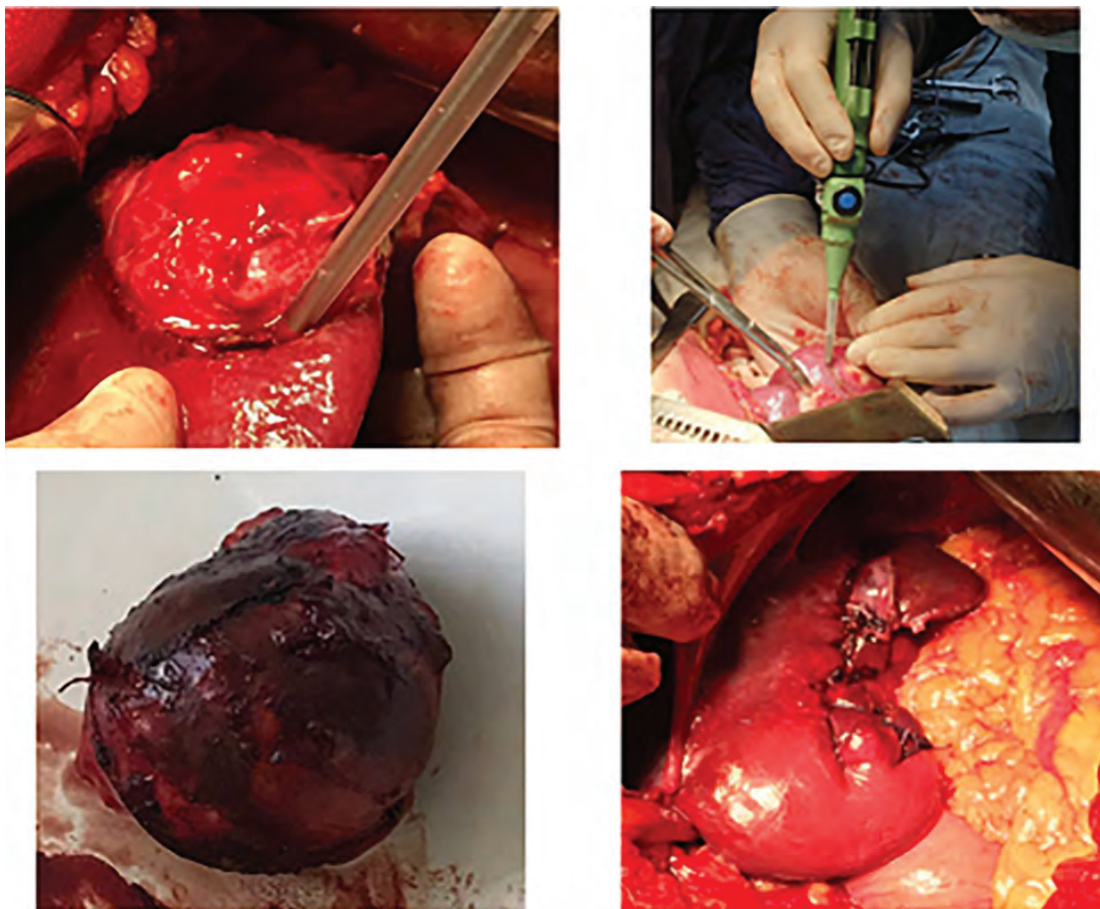
B.

Fig. 4. Our proposed instrument to straighten the folds in the residual cavity after echinococcectomy from the liver: A – initial position; B – in the opened position.



Since 2020, radical surgery has been performed using the cavitation ultrasonic dissector aspirator. The Sonoca 300 ultrasonic dissector aspirator is based on the principle of selective ultrasound treatment of parenchymal tissue.

The parenchymal tissue is disrupted and removed by suction. Cavitation-induced destruction, fluid delivery and tissue aspiration occur simultaneously due to the design of the working tool and the instrument. (Fig. 5).



**Fig. 5. Cyst excision with ultrasonic dissector aspirator – SONOCA 300.**

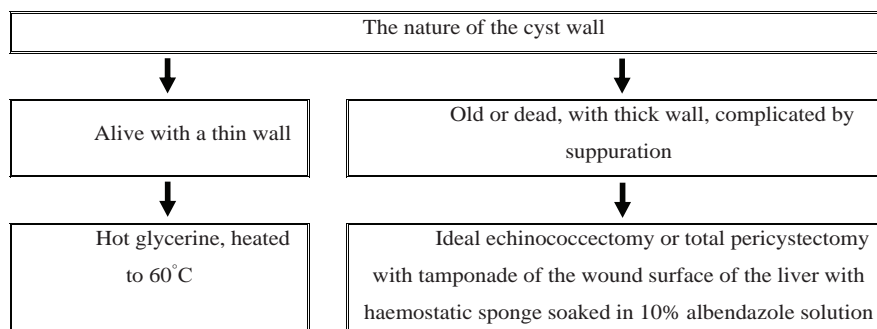
The use of ultrasonic dissector aspirator SONOCA 300 allows to apply more radical modern methods of surgical interventions in hepatic echinococcosis, to perform them bloodlessly, with good final hemo- and cholestasis with minimal traumatization of the exposed tissues. It allows to shorten the duration of surgery, reduce blood loss, perform effective antiparasitic treatment of cyst walls, provide reliable hemo- and cholestasis after traumatic interventions. Ultimately, it provides a significant improvement in the immediate results of surgical treatment of patients with hepatic echinococcosis and prevents recurrences of the disease.

After the widespread introduction of the ultrasonic aspirator dissector, total pericystectomy (18.6 %) and

perfect echinococectomy (11.4 %) were frequently performed, which had a positive impact on immediate and long-term outcomes.

In patients after complete echinococectomy and total pericystectomy, the wound surface of the liver was tamponaded with a hemostatic sponge impregnated with 10 % albendazole solution, which prolonged the local effect of the drug on the pathological focus.

According to the study, a sterile sponge of 7×5×1 cm was impregnated with 50 ml of 0.9 % physiological solution in which albendazole was dissolved at a concentration of 10 µg/mL. Based on this study, the authors propose an algorithm for the treatment of residual cavities (Fig. 6).



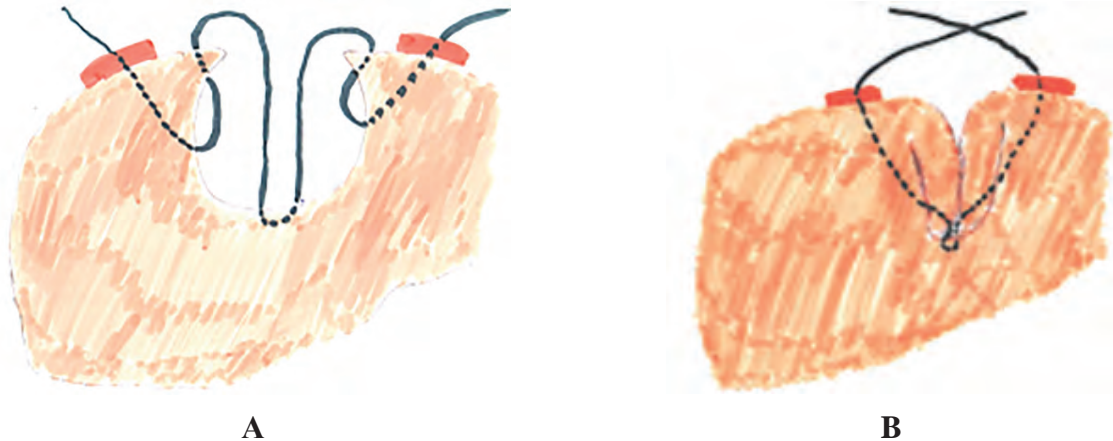**Fig. 6. Residual cavity treatment method.**

In case of a thin-walled fibrous capsule, we recommend treating the remaining cavity with hot glycerol heated to 60 °C. In case of old, dead echinococcal cysts, with thick calcified wall or complicated by suppuration, we recommend to perform perfect echinococectomy or open echinococectomy followed by total pericystectomy if possible. Then the wound surface of the liver is tamponed with a hemostatic sponge impregnated with 10 % albendazole solution.

After open echinococectomy since 2013, the residual cavity is eliminated according to the developed method by placing biological pads along the suture line (certificate

of official registration of the patent for invention No. IAP 07427, Intellectual Property Agency of the Republic of Uzbekistan «Method of residual cavity elimination after echinococectomy from the liver»). (Fig. 7).

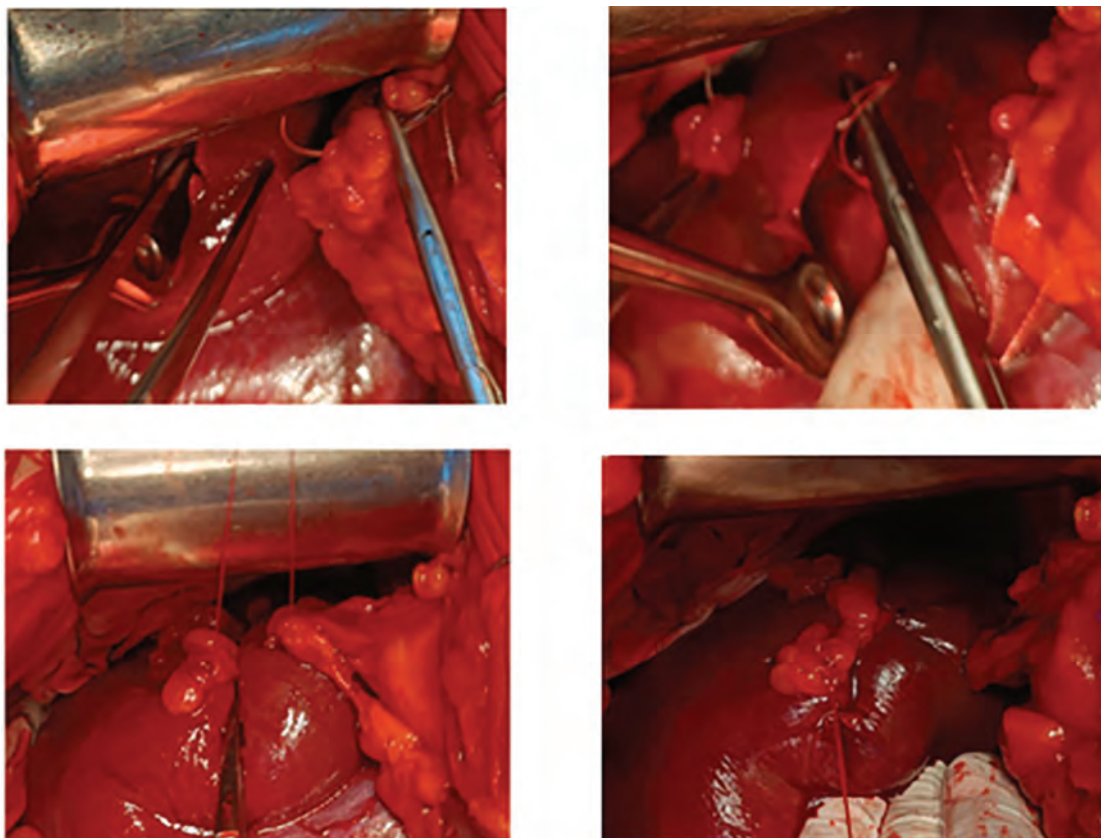
The advantage of using the suture on biological pads is that in order to eliminate the residual cavity according to the claimed method, several punctures and punctures are made to apply an immersion suture, while tightening the fibrous capsule requires a certain tension, which may lead to thread cutting in the zone of passing through the liver tissue, thus weakening the suture line and forming residual cavities.



**Fig. 7. Our proposed method of eliminating the residual cavity after echinococectomy from the liver: A – M-shaped suture; B – view after thread tightening.**

The use of biological pads in the areas of maximum tension helps to distribute the load on the liver tissue through

the safety pads, protecting it from excessive tension during tying and reducing the risk of suture cutting. (Fig. 8).



**Fig. 8. Steps of immersion sutures on biological pads.**

**Results of the research.** In patients with hepatic echinococcosis, the immediate results of surgical treatment were evaluated by the following indicators: Presence of intraoperative complications, course of postoperative period, presence or absence of bile flow through drains, suppuration of residual cavity, terms of drainage removal, nature of laparotomy wound healing, time of patient's stay in hospital (bed-day), duration of surgery (min), duration of temperature (day), ultrasound signs of intrahepatic and intra-abdominal pustules, recurrences and residual cysts.

Improvement of the choice of tactics of surgical treatment of patients with echinococcosis of abdominal cavity organs, technique of echinococectomy from different approaches with full exposure, evacuation of cyst contents by modified suction tip and «clamp-basket», method of detection of hidden

biliary fistulas in residual cavity, suturing of residual cavity by liquidation without leaving free area for fluid accumulation, use of ultrasonic dissector-aspirator – SONOCA 300 in perfect echinococectomy and total pericystectomy, and tamponade of the wound surface of the liver with hemostatic sponge impregnated with albendazole, as well as other innovations developed and implemented within the framework of this study, had a positive impact on the immediate results of the treatment of this category of patients. For example, intraoperative complications such as anaphylactic shock, parenchymal hemorrhage, infiltration of surrounding tissues with daughter bladders were rare compared to 2005-2012. Intraoperative complications decreased from 6.5 to 2.3 %, and early postoperative complications decreased from 18.2 to 5.2 % (Table 2).

Table 2.

Immediate results of surgical treatment of echinococcosis of abdominal organs

Type of complication	Comparison group, n=154		Main group, n=174		Total, n=328	
	abc.	%	abc.	%	abc.	%
Intraoperative complications						
Anaphylactic shock	2	1,3	1	0,6	3	0,9
Infiltration of echinococcal cysts into surrounding tissues	5	3,2	3	1,7	8	2,4
Parenchymal haemorrhage	3	1,9	0	0	3	0,9
Total intraoperative complications	10	6,5	4	2,3	14	4,3
Complications in the early postoperative period						
Residual cavity suppuration	7	4,5	1	0,6	8	2,4
Biliary fistula	9	5,8	4	2,3	13	3,9
Biliary peritonitis	2	1,3	0	0	2	0,6
Drainage haemorrhage	1	0,6	2	1,1	3	0,9
Subdiaphragmatic abscess.	3	1,9	0	0	3	0,9
Pleuritis	1	0,6	0	0	1	0,3
Postoperative wound suppuration	5	3,2	2	1,1	7	2,1
Total complications in the early postoperative period	28	18,2	9	5,2	37	11,3
Number of patients with complications in the early postoperative period	24	15,6	8	4,6	32	9,7

Anaphylactic shock during surgery was observed in 2 (1.3 %) patients in the control group, and infiltration of cyst contents into surrounding tissues was observed in 8 (2.4 %) cases, in 5 (3.2 %) patients in the control group, and in 3 (1.7 %) patients in the main group. These circumstances prompted us to improve the technical aspects of cyst evacuation.

Thus, the developed algorithm for the choice of tactics of surgical treatment of hepatic echinococcosis, taking into consideration the complex approach to the choice of access, method of treatment and elimination of the residual

cavity, allowed to improve the quality of care by reducing the incidence of immediate postoperative complications from 15.6 % (24 patients in the comparison group) to 4.6 % (8 patients in the main group) ( $\chi^2$  criterion = 4.954; Df=1; p=0.027).

Of the 328 patients, 227 (69.2 %) were examined in the distant postoperative period. Of the 227 patients examined in the distant postoperative period, recurrence of echinococcosis was noted in 23 (10.1 %) patients, while in the group of patients operated in 2005-2012, this figure reached 16.2 %. (Fig. 9).

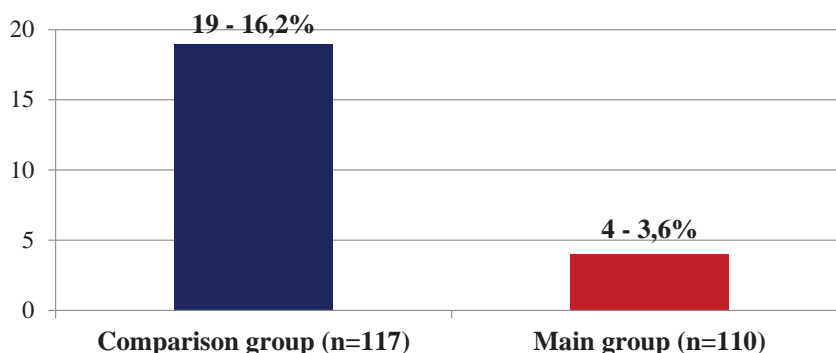


Fig. 9. Recurrence rate of hepatic echinococcosis.



## Conclusion

The proposed diagnostic algorithm of topical verification of echinococcosis localization in the liver, taking into account the number of cysts, their size, as well as the nature and presence of complications, made it possible to perform adequate echinococcectomy by minimally invasive methods in 39.1 % of cases in the main group, in particular by mini-access (34.5 %) and endovideosurgical method (2.9 %), thus reducing the frequency of traditional wide accesses to 61.5 %.

Introduction of improved surgical instruments – modified puncture needle, «clamp-basket» allowed to level the risk of contamination of surrounding tissues with germinal elements and reduced the number of intraoperative complications from 6.5 to 2.3 %. The introduction of the device for detection of hidden biliary fistulas in the residual cavity after echinococcectomy from the liver reduced the number of biliary fistulas from 5.8 % to 2.3 %, and biliary peritonitis from 1.3 % to 0.0 %. With the introduction into practice of the modified method of elimination of residual cavity after echinococcectomy from the liver, the number of complications during the operation and in the early postoperative period was minimized.

## References:

- Castillo S, Manterola C, Grande L, Rojas C. Infected hepatic echinococcosis. Clinical, therapeutic, and prognostic aspects. A systematic review. *Ann Hepatol* [Internet]. 2021 [cited 2024 Jun 6];22:100237. Available from: <https://www.sciencedirect.com/science/article/pii/S1665268120301423?via%3Dihub> DOI: <https://doi.org/10.1016/j.aohep.2020.07.009>
- Nazyrov FG, Shamsiev AM, Jeshonhodzhaev, Rahmanov KJe, Davlatov SS. Puti uluchsheniya rezul'tatov hirurgicheskogo lecheniya jehinokokkoza pecheni [Ways to improve the results of surgical treatment of liver echinococcosis]. *Neonatologist, surgery and perinatal medicine*. 2018;8(3):39-43. DOI: <https://doi.org/10.24061/2413-4260.VIII.3.29.2018.7> (in Russian)
- Schipper HG, Kager PA. Diagnosis and treatment of hepatic echinococcosis: an overview. *Scand J Gastroenterol Suppl*. 2004;39(241):50-5. DOI: <https://doi.org/10.1080/00855920410011004>
- Rakhmanov KE, Davlatov SS, Abduraxmanov DS. Correction of albendazole disease after echinococcectomy of the liver. *Intern J Pharm Research*. 2020;12(3):3851. DOI: <https://doi.org/10.31838/ijpr/2020.13.01.596>
- Thota A, Reddy AD, Rao VNV. Surgical treatment of abdominal echinococcosis. *Int Surg J*. 2018;5(12):3831-6. DOI: <http://dx.doi.org/10.18203/2349-2902.isj20184715>
- Shamsiev AM, Shamsiev ZhA, Rakhmanov KJe, Davlatov SS. Differencirovannaja lechebnaja taktika v hirurgii jehinokokkoza pecheni [Differentiated treatment tactics in surgery of liver echinococcosis]. *Experimental and Clinical Gastroenterology*. 2020;174(5):72-7. DOI: <http://dx.doi.org/10.31146/1682-8658-ECG-177-5-72-77> (in Russian)
- Nunnari G, Pinzone MR, Gruttadauria S, Celesia BM, Madeddu G, et al. Hepatic echinococcosis: clinical and therapeutic aspects. *World J Gastroenterol*. 2012;18(13):1448-58. DOI: <https://doi.org/10.3748/wjg.v18.i13.1448>
- Magistri P, Pecchi A, Franceschini E, Pesi B, Guadagni S, Catellani B, et al. Not just minor resections: robotic approach for cystic echinococcosis of the liver. *Infection*. 2019;47(6):973-9. DOI: <https://doi.org/10.1007/s15010-019-01333-2>
- Sapaev DS, Yakubov FR, Yakhshiboev SS. Evaluation of the factors influencing the choice of laparoscopic echinococcectomy in liver echinococcosis (LE) and its impact on postoperative outcomes. *Exp Parasitol* [Internet]. 2023 [cited 2024 Jul 2];248:108495. Available from: [https://linkinghub.elsevier.com/retrieve/pii/S0014-4894\(23\)00036-X](https://linkinghub.elsevier.com/retrieve/pii/S0014-4894(23)00036-X) DOI: <https://doi.org/10.1016/j.exppara.2023.108495>
- Yakubov FR, Sapaev DS. Surgical treatment of liver echinococcosis. *J Med Life*. 2022;15(11):1409-14. DOI: <https://doi.org/10.25122/jml-2022-0268>
- Schröder R, Robotti G. New aspects in the management of alveolar echinococcosis involving the liver. *World journal of surgery*. 1986;10(6):968-72. DOI: <https://doi.org/10.1007/bf01658648>
- Nagasbekov MS, Baimakhanov ZhB, Nurlanbayev EK, Kaniyev ShA, Chormanov AT, Baimakhanov BB. Modern approaches in the diagnostics and treatment of cystic liver echinococcosis. Literature review. *Bulletin of surgery in Kazakhstan*. 2022;73:36-42. DOI: <https://doi.org/10.35805/BSK2022IV040>
- Patkowski W, Krasnodebski M, Grąt M, Masior Ł, Krawczyk M. Surgical treatment of hepatic Echinococcus granulosus. *Gastroenterology Review/Przegląd Gastroenterologiczny*. 2017;12(3):199-202. DOI: <https://doi.org/10.5114/pg.2017.70473>
- Wan L, Wang T, Cheng L, Yu Q. Laparoscopic treatment strategies for liver echinococcosis. *Infect Dis Ther*. 2022;11(4):1415-26. DOI: <https://doi.org/10.1007/s40121-022-00664-2>
- Mihetiu A, Bratu DG, Sandu A, Sabau A, Sabau D. Specialized laparoscopic devices in the treatment of hydatid hepatic cysts: a retrospective analysis and review of the literature. *Cureus* [Internet]. 2024 [cited 2024 Jun 7];16(3): e55968. Available from: <https://www.ncbi.nlm.nih.gov/pmc/articles/PMC11006410/> DOI: <https://doi.org/10.7759/cureus.55968>
- da Silva AM. Cystic Echinococcosis in the Liver: Nomenclature and Surgical Procedures. *J Surg Surgical Res*. 2015;1(3):59-65. DOI: <http://dx.doi.org/10.17352/2455-2968.000015>
- Manterola C, Otzen T. Hepatic echinococcosis with thoracic involvement. Clinical characteristics of a prospective series of cases. *Ann Hepatol*. 2017;16(4):599-606. DOI: <https://doi.org/10.5604/01.3001.0010.0305>

The use of ultrasonic dissector-aspirator SONOCA 300 allows to apply radical modern methods of surgical interventions at echinococcosis more widely, to perform them bloodlessly, with good final hemo- and cholestasis, with minimal traumatization of tissues in the area of exposure with destruction and aspiration of pericystic parenchyma, which reduces to zero the probability of leaving germinal elements of echinococcal cyst in this area. After tamponing with a hemostatic sponge impregnated with 10 % albendazole solution with exposure for 7-10 minutes, in all cases only dead and destroyed germinal elements of the parasite were found in the wash from the wound surface of the liver.

The developed algorithms of choice of tactics of surgical treatment of echinococcosis, taking into account the complex approach to the choice of access, mainly to radical echinococcectomy and elimination of residual cavity, as well as prophylactic chemotherapy, allowed to improve the quality of care by reducing the incidence of immediate postoperative complications from 15.6 to 4.6 % (p=0.027 by  $\chi^2$  criterion) and disease recurrence from 16.2 % to 3.6 % (p=0.031 by  $\chi^2$  criterion). (p=0.027 by  $\chi^2$  criterion) and disease recurrence from 16.2 % to 3.6 % (p=0.031 by  $\chi^2$  criterion).

## АСПЕКТИ ХІРУРГІЧНОГО ЛІКУВАННЯ ЕХІНОКОКОЗУ ПЕЧІНКИ

К. Рахманов<sup>1</sup>, Д. Раджабов<sup>1</sup>, С. Давлатов<sup>2</sup>, Б. Хамдамов<sup>2</sup>, С. Янченко<sup>2</sup>, Р. Наврузов<sup>2</sup>Самаркандський державний медичний університет<sup>1</sup> (Самарканд, Узбекистан),Бухарський державний медичний інститут імені Абу Алі ібн Сіно<sup>2</sup> (Бухара, Узбекистан)**Резюме.**

За даними ВООЗ, «...у будь-який момент часу ехінококозом уражено понад 1 мільйон людей у всьому світі...». У зв'язку з відсутністю тенденції до зменшення кількості хворих та існуванням ендемічних регіонів, де рівень захворюваності коливається від 1,2 до 9,0 на 100 000 населення, це паразитарне захворювання продовжує залишатися серйозною медико-соціальною проблемою. На сучасному етапі діагностика ехінококозу не представляє значних труднощів, в основному завдяки появі неінвазивних методів візуалізації, інформативність комплексного застосування яких досягає 95-100 %.

**Мета дослідження.** Покращення результатів лікування хворих на ехінококоз печінки.

**Матеріали дослідження.** У дослідження включено 328 хворих на ехінококоз печінки, які поступили до хірургічного відділення багатопрофільної клініки Самаркандського державного медичного університету в період з 2005 по 2023 роки. Залежно від вибору методу лікування пацієнти були розподілені на дві групи: групу порівняння склали 154 (46,9 %) пацієнта, прооперовані за період з 2005 по 2012 рр., а основну групу – 174 (53,0 %) пацієнта, прооперовані за період з 2013 по 2023 рр.

**Результати дослідження.** Порівняно з групою порівняння, в основній групі пацієнтів інтраопераційні ускладнення зменшилися з 6,5 до 2,3 %, а ускладнення в ранньому післяопераційному періоді – з 18,2 до 5,2 %. У пізньому післяопераційному періоді рецидиви захворювання зменшилися з 16,2 % до 3,6 %.

**Висновки.** Впровадження в практику удосконаленого хірургічного інструментарію – модифікованої пункційної голки, «кошикового затискача» дозволило нівелювати ризик засіву навколишніх тканин ембріональними елементами. Впровадження пристрою для виявлення прихованих жовчних нориць у залишковій порожнині після ехінококетомії з печінки дозволило зменшити кількість підтікань жовчі. При впровадженні модифікованого способу ліквідації залишкової порожнини після ехінококетомії з печінки кількість ускладнень під час операції та в ранньому післяопераційному періоді була зведена до мінімуму.

**Ключові слова:** печінка; ехінококоз; хірургічне лікування.

**Contact information**

**Kosim Rakhmanov** – DSc, Associate Professor of the Department of Surgical Diseases No. 1, Transplantology and Urology, Samarkand State Medical University (Samarkand, Uzbekistan).  
**e-mail:** qosimmedik@mail.ru  
**ORCID ID:** <https://orcid.org/0000-0002-3898-504X>  
**Scopus Author ID:** <https://www.scopus.com/authid/detail.uri?authorId=57219193715>

**Jasur Radjabov** – Assistant of the Department of General Surgery, Samarkand State Medical University (Samarkand, Uzbekistan).  
**e-mail:** jasurxirurg1984@gmail.com  
**ORCID ID:** <https://orcid.org/0009-0005-3680-3475>

**Salim Davlatov** – Associate Professor of the Department of Faculty and Hospital Surgery, Bukhara State Medical Institute named after Abu Ali ibn Sino (Bukhara, Uzbekistan).  
**e-mail:** pro.ilmiy@bsmi.uz  
**ORCID ID:** <https://orcid.org/0000-0002-3268-7156>  
**Scopus Author ID:** <https://www.scopus.com/authid/detail.uri?authorId=57219956374>

**Bakhtiyor Khamdamov** – DSc, Professor, Head of Department of the Faculty and Hospital Surgery, Bukhara State Medical Institute named after Abu Ali ibn Sino (Bukhara, Uzbekistan).  
**ORCID ID:** <https://orcid.org/0000-0003-3569-6688>  
**e-mail:** dr.hamdamov@mail.ru  
**Scopus Author ID:** <https://www.scopus.com/authid/detail.uri?authorId=57221665311>

**Sergey Yanchenko** – MD, PhD, DSc, Associative Professor, Professor of Ophthalmology Department of Bukhara State Medical Institute named after Abu Ali ibn Sino (Bukhara, Uzbekistan).  
**e-mail:** eye2105sv@gmail.com  
**ORCID ID:** <https://orcid.org/0000-0002-7371-689X>  
**Scopus Author ID:** <https://www.scopus.com/authid/detail.uri?authorId=57192961634>

**Navruzov Rustam Rashidovich** – Associate Professor of the Department of Nuclear Medicine and Medical Radiology of the Bukhara State Medical Institute named after Abu Ali ibn Sino. Bukhara, Uzbekistan  
**ORCID ID:** <https://orcid.org/0000-0002-8848-0795>  
**e-mail:** rustam.navruzov.9191@gmail.com  
**Scopus Author ID:** <https://www.scopus.com/authid/detail.uri?authorId=59243575200>

**Контактна інформація**

**Рахманов Касим Ерданович** – доктор медичних наук, доцент кафедри хірургічних хвороб № 1, трансплантології та урології Самаркандського державного медичного університету (м. Самарканд, Узбекистан)  
**e-mail:** qosimmedik@mail.ru  
**ORCID ID:** <https://orcid.org/0000-0002-3898-504X>  
**Scopus Author ID:** <https://www.scopus.com/authid/detail.uri?authorId=57219193715>

**Раджабов Жасур Пардабаєвич** – асистент кафедри загальної хірургії Самаркандського державного медичного університету (м. Самарканд, Узбекистан).  
**e-mail:** jasurxirurg1984@gmail.com  
**ORCID ID:** <https://orcid.org/0009-0005-3680-3475>

**Давлатов Салім Сулаймонович** – доцент кафедри факультетської та госпітальної хірургії Бухарського державного медичного інституту імені Абу Алі ібн Сіно (м. Бухара, Узбекистан).  
**e-mail:** pro.ilmiy@bsmi.uz  
**ORCID ID:** <https://orcid.org/0000-0002-3268-7156>  
**Scopus Author ID:** <https://www.scopus.com/authid/detail.uri?authorId=57219956374>

**Хамдамов Бахтієр Заріфович** – доктор медичних наук, професор, завідувач кафедри факультетської та госпітальної хірургії Бухарського державного медичного інституту імені Абу Алі ібн Сіно (м. Бухара, Узбекистан).  
**e-mail:** dr.hamdamov@mail.ru  
**ORCID ID:** <https://orcid.org/0000-0003-3569-6688>  
**Scopus Author ID:** <https://www.scopus.com/authid/detail.uri?authorId=57221665311>

**Янченко Сергій Володимирович** – доктор медичних наук, доцент, професор кафедри офтальмології Бухарського державного медичного інституту імені Абу Алі ібн Сіно (м. Бухара, Узбекистан).  
**e-mail:** eye2105sv@gmail.com  
**ORCID ID:** <https://orcid.org/0000-0002-7371-689X>  
**Scopus Author ID:** <https://www.scopus.com/authid/detail.uri?authorId=57192961634>

**Наврузов Рустам Рашидович** – доцент кафедри ядерної медицини і медичної радіології Бухарського державного медичного інституту імені Абу Алі ібн Сіно. Бухара, Узбекистан.  
**ORCID ID:** <https://orcid.org/0000-0002-8848-0795>  
**e-mail:** rustam.navruzov.9191@gmail.com  
**Scopus Author ID:** <https://www.scopus.com/authid/detail.uri?authorId=59243575200>

