

UDC: 617.54-002.3-072.1-053.3

DOI: 10.24061/2413-4260. XIV.2.52.2024.23

**S. Babuci, V. Negru, I. Ambros,
I. Revenco, D. Haidarlî**

Mother and Child Institute (Kishinev, Republic of Moldova),
National Scientific-Practical Center of Pediatric Surgery
«Natalia Gheorghiu» (Kishinev, Republic of Moldova),
State University of Medicine and Pharmacy «Nicolae Testemitanu» (Kishinev, Republic of Moldova)

VIDEO-ASSISTED THORACOSCOPIC SURGERY IN A 35-DAY-OLD INFANT WITH MULTILOCULATED THORACIC EMPYEMA: CASE REPORT

Summary

The authors report a clinical case of a 35-day-old infant with multiloculated thoracic empyema who was successfully operated on by the surgical team. The infant was transferred from a regional medical facility with fever, low-productive cough, and dyspnea. The disease had started 7 days earlier, but despite 5 days of antibiotic treatment in the hospital of his place of residence, the child's condition continued to deteriorate, so he was transferred to the pediatric intensive care unit of our institution. After admission, a CT scan revealed massive closed fluid collections with subpleural localization in the right hemithorax and in the projection of the anterior mediastinum associated with subtotal atelectasis of the right lung, closed pleurisy without signs of lung tissue destruction, suspicion of intrathoracic cystic lymphangioma. The patient underwent video-assisted thoracoscopic surgery, during which several purulent localized collections were identified, which were opened and drained with a volume of approximately 200 ml of viscous purulent fluid. The postoperative period was difficult but favorable. 6 months later, CT and scintigraphy showed some insignificant residual lung changes and diffuse perfusion changes, confirming the slow regression of the septic inflammatory process of the pleural cavity after resolution.

The authors conclude that the presented case highlights the difficulties of imaging differential diagnosis and suggests that VATS is an effective and safe treatment option for infants with pleural empyema, especially in multiloculated fibrinopurulent forms, allowing a favorable outcome with a short duration of thoracostomy with tube and comparatively short recovery and hospitalization periods.

Key words: Empyema; Multiloculated; Lung; VATS; Infant.

Thoracic empyema is the accumulation of pus in the pleural cavity, which is quite common in children, usually as a complication of bacterial pneumonia. Thoracic empyema is less common in the neonatal period or in infants due to the immaturity of the immune system, which limits the localization of infection to the pleural space and the ability of the pleura to produce sufficient exudate [1]. The incidence of pleural empyema in children has increased significantly in the last 20 years in developed countries, being a complication of bacterial pneumonia in 0.6 % [2], representing approximately 3.5-12.5 cases per 100,000 children, with a morbidity and mortality rate of up to 10 %. At the same time, pleural empyema is a rare entity in the neonatal period with an estimated incidence of 20-440 cases per 20,000 neonatal admissions. These data have led to a significant focus of research on this infection, the analysis of local epidemiologic data, as well as the evaluation of some factors that could determine the progression of pneumonia to complicated forms with empyema, which are currently uncertain [3, 4, 5, 6].

The main goal of treatment of thoracic empyema is to limit the manifestations of sepsis by evacuating and sterilizing the pleural space, thereby restoring circulation and function of the pleural fluid. Incomplete drainage of the pleural space contributes to persistent infection, which would cause functional impairment and significant morbidity and mortality. To prevent this, prompt surgical intervention is required. However, the decision of the appropriate treatment (surgical or non-surgical) is a vexing clinical issue due to the lack of specific clinical, radiological and laboratory features

for the appropriate preoperative staging of empyema, with no current consensus on the surgical management of this pathology in children [7, 8, 9, 10]. In this context, we present a clinical case of a 36-day-old infant with subtotal pneumonia of the right lung complicated by empyema.

Presentation of the case.

Male infant U.M., 36 days old, born at 39-40 weeks of gestation by uncomplicated spontaneous vaginal delivery, weighing 3370 g, was transferred from a regional medical center with fever, low-productive cough and dyspnea with the referral diagnosis of acute community-acquired pneumonia: Acute community-acquired pneumonia of the right side. Atelectasis in the right upper lobe. Leukemoid reaction? Suspected leukemia?

The maternal history was unremarkable. The neonatal period was normal, the child was vaccinated according to the calendar.

The disease started 7 days earlier, for which he was admitted to the hospital of his place of residence. Despite antibiotic treatment for 5 days, the child's condition continued to deteriorate, so he was transferred to the pediatric intensive care unit with the admission diagnosis: Subtotal pneumonia on the right, pleuropulmonary form; atelectasis of the upper lobe on the right; exudative-fibrinous pleurisy on the right. Sepsis. MODS.

Physical examination: the child was somnolent, with tachypnea (66 beats per minute), with participation of auxiliary muscles, intercostal and subcostal retraction. Heart rate – 164 beats per minute, blood pressure – 107/81 mmHg, SpO₂-93 % with wet O₂ by mask 2 l/min.

Labs: RBC – $3.0 \times 10^{12}/L$; Hb concentration – 105 g/L, marked leukocytosis (leukocytes – $49 \times 10^9/L$) with deviation to the left of the leukocyte formula (neutrophils: unsegmented – 20 %, segmented – 47 %, metamyelocytes 6 %, myelocytes 8 %, lymphocytes – 10 %, eosinophils – 0 %, monocytes 9 %, toxic granulation +++), platelets was $568 \times 10^9/L$, total protein was 49.0 g/l. Arterial blood gas test showed: pH – 7.35; pCO_2 – 36.6 mmHg; pO_2 – 61.2 mmHg. Blood biochemistry test found: Alanine aminotransferase – 9 U/L, aspartate aminotransferase – 13 U/L; creatinine – 64

mcmol/l; fibrinogen – 6.60 g/l; Na^+ – 134 mmol/l; K^+ – 3.8 mmol/kg, Ca^{+} – 2.26 mmol/l, Cl^- – 106 %, glucose – 4.2 mmol/l., ESR – 30 mm/hour. Blood culture – negative.

Computed tomography showed massive closed fluid collections with subpleural localization in the right hemithorax and at the level of the anterior mediastinum associated with subtotal atelectasis of the right lung. Closed pleurisy without evidence of lung tissue destruction; intrathoracic cystic lymphangioma? Moderate displacement of the mediastinum to the left.

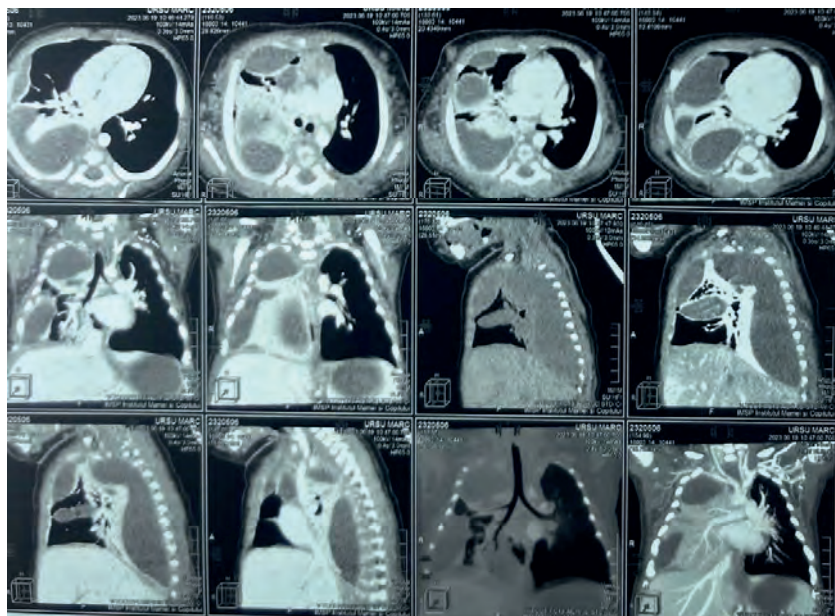


Fig. 1. Child U.M., aged 36 days. Computed tomography performed preoperatively on the 9th day after the onset of the disease (explanations in the text)

Tc99m MAA lung scintigraphy performed preoperatively showed that the right lung was reduced in size, with an unclear and irregular contour, with uneven distribution of the radio-

pharmaceutical and with a sudden diffuse decrease in pulmonary blood flow, with multiple areas of no pulmonary perfusion in the upper segments. Left lung with no perfusion changes.

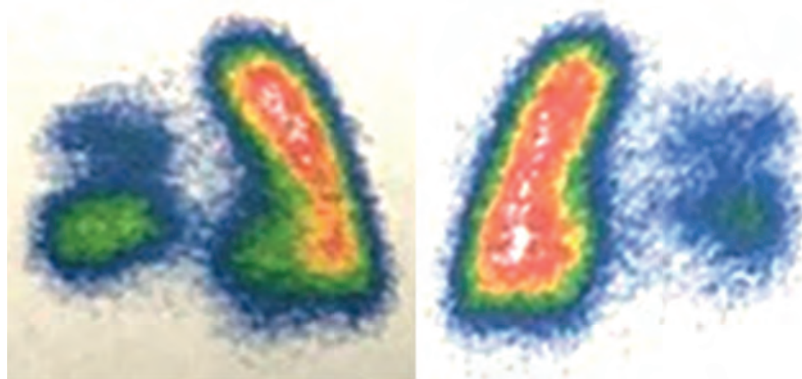


Fig. 2. Child U.M., Preoperative perfusion lung scintigraphy (explanations in the text)

After the administered treatment, including antibiotic therapy, although the fever and the intensity of the toxic syndrome decreased in intensity, the persistence of dyspnea and subcostal retraction were determined, which, along with some diagnostic imaging problems, served as indications for video-assisted thoracoscopy.

After treatment, including antibiotic therapy, although the fever and toxic syndrome decreased in intensity, persistent dyspnea and subcostal retraction were noted, which, along

with some diagnostic imaging problems, served as an indication for video-assisted thoracoscopy.

Examination with a 3-mm thoracoscope (0°; Richard Wolf, Germany) revealed free purulent fluid, viscous, yellow-green in color, which was aspirated in a volume of approximately 200 ml, as well as several purulent collections localized by adhesions, which were later removed. The pleura was apparently thickened with considerable fibrin deposits, which were removed. The pleural cavity was

lavaged with aminocaproic acid, Betadine solution and drained with a 12 F tube.

The postoperative period was difficult, the child was on assisted ventilation for the first 4 hours postoperatively, after which spontaneous breathing was restored. The chest tube was removed on postoperative day 10. Bacteriological results from the purulent pleural fluid showed no growth, while *S.aureus*, *Corynebacter* spp. and *Candida* were detected in the throat swab.

The patient was discharged on postoperative day 25 (hospital day 32) in satisfactory condition. The follow-up

radiologic examination performed at discharge showed normal lung volume with an enhanced and distorted lung pattern without free air and fluid in the pleural cavity. Reaction of the interlobular pleura in regression. The pneumonic infiltrate was practically completely resolved. The thickening of the paracostal pleura on the right side is preserved. The mediastinum is normal. The scintigraphy performed at discharge showed uneven distribution of the radiopharmaceutical in the right lung, unclear contour of the upper zone with restoration of the medio-basal contour and pulmonary blood flow. On the left side there were no changes in pulmonary perfusion.

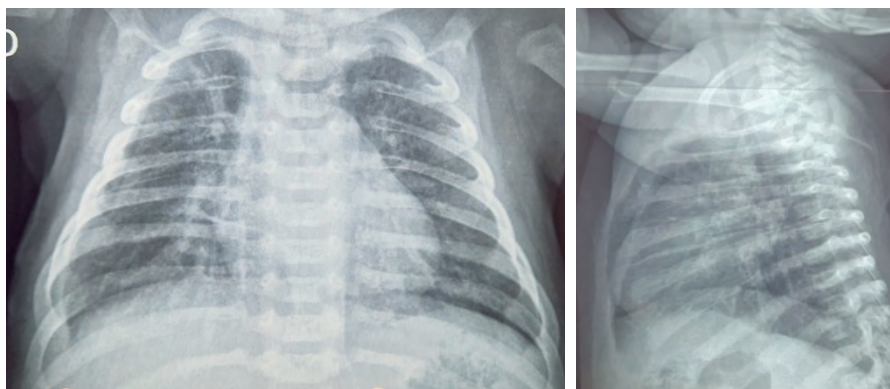


Fig. 3. Child U.M. Chest X-ray in 2 projections performed at the time of discharge.

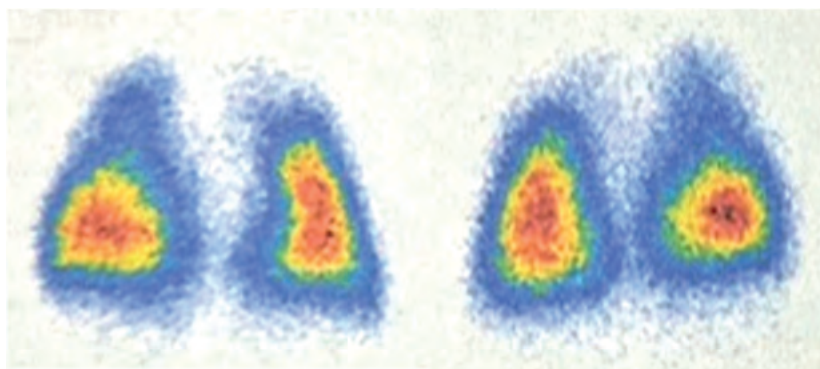


Fig. 4. Child U.M., Pulmonary scintigraphy by perfusion performed at discharge (explanations in the text).

6 months after discharge, a favorable clinical evolution was observed, the child grew according to his age without any symptoms. Although some insignificant residual lung changes were detected on CT (Fig. 5), diffuse perfusion

changes of the left lung were observed on lung scintigraphy (Fig. 6). These data confirm the slow regression of residual changes after resolution of the septic inflammatory process of the pleural cavity in infants.

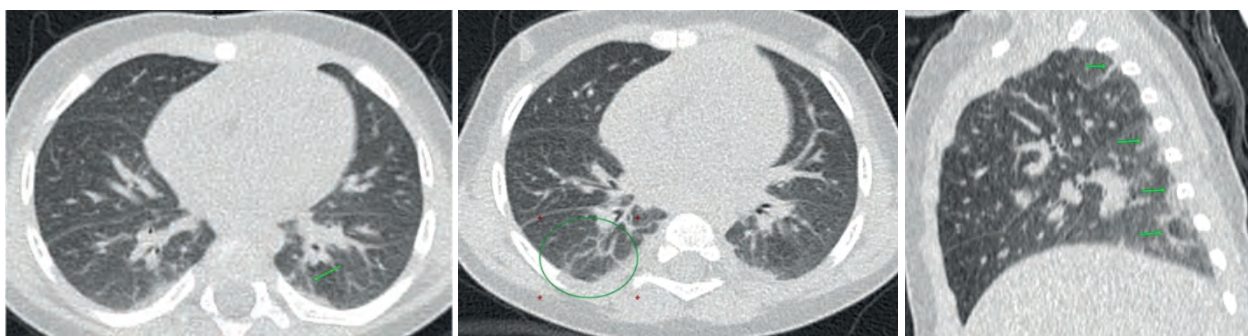


Fig. 5. Patient U.M. Computed tomography performed 6 months after discharge. Imaging data suggestive of bilateral diffuse pneumofibrotic changes

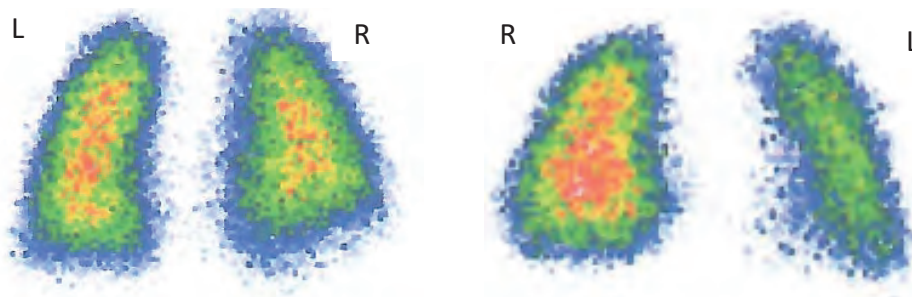


Fig. 6. Patient U.M. Pulmonary perfusion scintigraphy in two incidences (anterior and posterior) performed 6 months after discharge. The uneven distribution of the radiopharmaceutical was detected bilaterally, with the preservation of the blood flow within the limits of normal values in the right lung, in the left lung being observed the diffuse decrease of the pulmonary blood flow more evident in the anterior segments

Discussions. Empyema is a purulent collection of the pleural space of various etiologies and is a serious, potentially fatal complication of pneumonia, chest trauma, infected hemothorax or surgery, after lung resection or iatrogenically during thoracentesis or intercostal tube insertion. It is characterized by effusions and fibrinopurulent collections, which can lead to pulmonary constriction and resistance to drainage [11, 12].

Although the incidence of pneumonia has decreased with the introduction of the pneumococcal conjugate vaccine, several reports have indicated an increase in the incidence of thoracic empyema in children in recent decades [13]. According to some authors, pleural effusions and parapneumonic empyema are found in 10 % to 40 % of all children hospitalized with bacterial pneumonia, with the main pathogens being serotype 1 and serotype 3 *Streptococcus*, both of which are included in the 13-valent pneumococcal conjugate vaccine (PCV13), which has been used for standard vaccination of infants from 2 months of age in Germany since 2009 to prevent invasive pneumococcal disease [14, 15, 16]. Of note, the overall detection rate of bacteria in blood and/or pleural fluid is approximately 29 % – 34 %. According to some studies, the majority (87 %) of the bacteria detected belonged to the group of gram-positive aerobic cocci, with *S. pneumoniae*, *S. pyogenes* and *S. aureus* being the most common of the 41 species reported, while the gram-negative aerobic bacteria (*P. aeruginosa*, *E. coli*, *Klebsiella pneumoniae*, *Francisella tularensis*) were found quite rarely in 5.7 % and anaerobic bacteria in 2.6 % [17, 18]. Few cases of empyema in young children following SARS-CoV-2 infection have been reported, including unique cases of co-infection with SARS-CoV-2 and *S. aureus* in a premature neonate complicated by thoracic empyema [19].

The concept that bacteria invade the visceral pleura to develop an infected parapneumonic effusion has recently been challenged because of differences between the typical bacteriology of pneumonia and thoracic empyema, and because many patients with empyema have no evidence of underlying pneumonia. In this regard, it has been suggested that in some cases pleural empyema and pneumonia should be considered as separate entities, as the mechanisms and sources of bacterial invasion are unclear [18, 20, 21].

According to the American Thoracic Society (1962), the course of pleural infection is characterized by three

distinct phases. The first (exudative) phase is characterized by a sterile, transparent exudate resulting from increased permeability of the visceral pleura. The second phase (fibrinopurulent) is associated with infection of the exudate by the initial invading pathogen and is characterized by the deposition of fibrin on the surface of the visceral and parietal pleura, leading to the formation of loculations and/or adhesions. The third phase (organization or consolidation) is characterized by the growth of fibroblasts and the formation of granulation tissue and a non-elastic lung lining [22, 23].

Chest radiography, ultrasonography, and chest computed tomography allow visualization of the presence of massive pleural effusion and the area of atelectasis or consolidation of the affected lung [6], which also requires differential diagnosis with some cystic congenital malformations [1]. In the presented case, although the CT scan allowed evaluation of the lung parenchyma and provided an accurate anatomical representation of the pathology, the differential diagnosis of multilocular effusion with a bulky intrathoracic cystic process was difficult.

Although thoracic empyema was known as early as Hippocrates, real progress in the treatment of this pathology occurred only in the mid-19th century, when Roe (1844) introduced repeated aspiration instead of simple knife incision. Later, Goodfellow and de Morgan (1859) proposed intercostal drainage [24].

The medical-surgical management of thoracic empyema is quite controversial and further studies are needed to investigate the efficacy of chest tube drainage as a first-line treatment [6, 25], with some studies reporting failure rates between 38 % and 47 %, and failure of first-line treatment being associated with increased mortality [26].

Some authors indicate the effectiveness of intrapleural use of fibrinolytics in the treatment of pleural empyema in adults and children [27], including neonates [19]. According to some studies, intrapleural fibrinolytic therapy in the early stages of the disease with both tissue plasminogen activator and streptokinase was safe and successful in patients with complicated parapneumonic pleurisy and empyema [28]. However, the role of fibrinolytic therapy in the treatment of pediatric pleural empyema is not clear, and the safety profile and conflicting results remain uncertain and concerning due to adverse effects and complications such as bleeding, allergic reactions, severe pain. The recent Cochrane systematic review showed that fibrinolytic therapy

is associated with longer duration of chest tube drainage, longer duration of fever, higher rates of need for analgesia, and increased total cost of care [29, 30, 31, 32].

In cases of inefficiency of first-line treatment with worsening of pleural empyema and progression to the fibropurulent or organizing phase, surgical debridement is required, with open thoracotomy being the conventional approach, a method associated with pain and significant postoperative morbidity [33]. Recent studies have shown that VATS performed in the early stage of the disease is technically easier, allows better drainage and has a higher probability of achieving full lung expansion, as well as being a method that significantly improves the recovery time and shortens the inpatient treatment period, including in young children [31, 34]. Although minimally invasive

surgical techniques may offer additional treatment options, their exact role in the treatment of pleural empyema is still unknown and requires new complex studies in the future [35].

Therefore, the presented case highlights the difficulties of imaging differential diagnosis and suggests that VATS is an effective and safe treatment option for infants with pleural empyema, especially in multiloculated fibrinopurulent forms, which allows a favorable evolution with a low duration of thoracostomy with tube and comparatively short recovery and hospitalization periods.

Conflict of interest: none

Source of financing: self-financing

References:

1. Nugraha HG, Hutapea YA. A rare case of multiloculated thoracic empyema in a neonate. *Radiol. Case Rep.* 2022;17(6):2181-5. doi: 10.1016/j.radcr.2022.03.089
2. Scarci M, Zahid I, Bille A, Routledge T. Is video-assisted thoracoscopic surgery the best treatment for paediatric pleural empyema? *Interact Cardiovasc Thorac Surg.* 2011;13(1):70-6. doi: 10.1510/icvts.2010.254698
3. Elemraid MA, Thomas MF, Blain AP, Rushton SP, Spencer DA, Gennery AR, et al. Risk factors for the development of pleural empyema in children. *Pediatr Pulmonol.* 2015;50(7):721-6. doi: 10.1002/ppul.23041
4. Krenke K, Urbankowska E, Urbankowski T, Lange J, Kulus M. Clinical characteristics of 323 children with parapneumonic pleural effusion and pleural empyema due to community acquired pneumonia. *J Infect Chemother.* 2016;22(5):292-7. doi: 10.1016/j.jiac.2016.01.016
5. Amin M, Yousef S, Navidifar T. Detection of the major bacterial pathogens among children suffering from empyema in Ahvaz city, Iran. *J Clin Lab Anal*[Internet]. 2019[cited 2024 Jan 3];33(4): e22855. Available from: <https://onlinelibrary.wiley.com/doi/10.1002/jcla.22855> doi: 10.1002/jcla.22855
6. Diez JRV, Perez MLM, Malayan GV, Cenabre MVL. Loculated empyema in a neonate successfully treated with chest tube thoracostomy and antibiotics. *Resp Med Case Rep*[Internet]. 2020[cited 2024 Jan 13];31:101274. Available from: [https://linkinghub.elsevier.com/retrieve/pii/S2213-0071\(20\)30488-3](https://linkinghub.elsevier.com/retrieve/pii/S2213-0071(20)30488-3) doi: 10.1016/j.rmcr.2020.101274
7. Manasa G, Swetha B, Yashoda HT, Pramod S. Paediatric empyema: video assisted thoracoscopic surgery (vats) and its outcome study. *Int J Contemp Pediatr.* 2017;4(3):882-5. doi: 10.18203/2349-3291.ijcp20171691
8. Sehitiogullari A, Sayir F, Aydemir Y, Anbar R, Sayhan H. Managing postpneumonic empyema thoracis in children: Comparison of different treatment options. *Iran J Pediatr*[Internet]. 2019[cited 2024 Jan 3]; 29(5): e86897. Available from: <https://brieflands.com/articles/ijp-86897> doi: 10.5812/ijp.86897
9. Shankar G, Sahadev R, Santhanakrishnan R, Pediatric empyema thoracis management: should the consensus be different for the developing countries? *J Pediatr Surg.* 2020;55(3):513-7. doi: 10.1016/j.jpedsurg.2019.08.009
10. Manoharan A, Lodha R. Debate 1: Is the management of childhood empyema primarily medical, or surgical? *Indian J Pediatr.* 2023;90(9):910-4. doi: 10.1007/s12098-023-04576-y
11. Elkhayat H, Sallam M, Kamal M, Abdalla EM. Thoracoscopic decortication for stage III empyema; a minimal invasive approach in a delayed presentation disease. *J Egyptian Soc Cardio-Thor Surg.* 2018;26(4):301-7. doi: 10.1016/j.jescts.2018.10.003
12. Karandashova S, Florova G, Idell S, Komissarov AA. From bedside to the bench – A call for novel approaches to prognostic evaluation and treatment of empyema. *Front.Pharmacol*[Internet]. 2022[cited 2024 Jan 9]; 12:806393. Available from: <https://www.frontiersin.org/journals/pharmacology/articles/10.3389/fphar.2021.806393/full> doi: 10.3389/fphar.2021.806393
13. Sakran W, Ababseh ZED, Miron D, Koren A. Thoracic empyema in children: Clinical presentation, microbiology analysis and therapeutic options. *J Infect Chemother.* 2014;20(4):262-5. doi: 10.1016/j.jiac.2013.12.006
14. Shatila M, Arab WA, Fasih N, Karara K, Ramadan AM. Comparative study between outcome of intercostal tube drainage and video assisted thoracoscopic surgery in management of complicated parapneumonic effusion in children. *J Egyptian Soc Cardio-Thor Surg.* 2018;26(1):68-72. doi: 10.1016/j.jescts.2017.12.002
15. Sorg AL, Obermeier V, Liese JG, von Kries R. Incidence trends of parapneumonic pleural effusions/empyema in children 2009 to 2018 from health insurance data: Only temporal reduction after the introduction of PCV13. *Vaccine.* 2021;39(26):3516-9. doi: 10.1016/j.vaccine.2021.05.005
16. Moral L, Toral T, Marco N, Clavijoc A, Canals F, Forniés MJ, et al. Epidemiology of pediatric parapneumonic pleural effusion during 13-valent pneumococcal conjugate vaccine implementation. *Enferm Infec Microbiol Clín.* 2023;41(7):414-9. doi: 10.1016/j.eimce.2022.08.007
17. Liese JG, Schoen C, van der Linden M, Lehmann L, Goettler D, Keller S, et al. Changes in the incidence and bacterial aetiology of paediatric parapneumonic pleural effusions/empyema in Germany, 2010-2017: a nationwide surveillance study. *Clin Microbiol Infect.* 2019;25(7):857-64. doi: 10.1016/j.cmi.2018.10.020
18. Dyrhovden R, Nygaard RM, Patel R, Ulvestad E, Kommdal O. The bacterial aetiology of pleural empyema. A descriptive and comparative metagenomic study. *Clin Microbiol Infect.* 2019;25:981-6. doi: 10.1016/j.cmi.2018.11.030
19. Sabzevari F, Sinaei R, Gholami A, Tahmasbi F. Empyema thoracic in a neonate co-infected with SARS-CoV-2 and staphylococcus aureus successfully treated with fibrinolysis: a brief report. *BMC Pediatrics.* 2023;23(1):552. doi: 10.1186/s12887-023-04375-6

20. Tobin CL, Lee YC. Pleural infection: what we need to know but don't. *Curr Opin Pulm Med.* 2012;18(4):321-5. doi: 10.1097/MCP.0b013e328352c673
21. Corcoran JP, Wrightson JM, Belcher E, DeCamp MM, Feller-Kopman D, Rahman NM. Pleural infection: past, present, and future directions. *Lancet Respir Med.* 2015;3(7):563-77. doi: 10.1016/S2213-2600(15)00185-X
22. Wurnig PN, Wittmer V, Pridun NS, Hollaus PH. Video-assisted thoracic surgery for pleural empyema. *Ann Thorac Surg.* 2006;81(1):309-13. doi: 10.1016/j.athoracsur.2005.06.065
23. Zhou Y, Li X, Dai J, Lin L, Cao X, Liu X, et al. Uniportal thoroscopic decortication for stage III tuberculous empyema with severe rib crowding. *Ann Thorac Surg.* 2021;112(1):289-94. doi: 10.1016/j.athoracsur.2020.07.067
24. Chaplin AE. Empyema thoracis in infant and children. *Arch Dis Child.* 1947;22(110):91-105. doi: 10.1136/adc.22.110.91
25. Sharma S, Sharma A, Sharma M, Ghosh S. Neonatal empyema thoracis. *Pediatr Oncall J.* 2018;15(1):19-21. doi: 10.7199/ped.oncall.2018.2
26. Semenovich TR, Olsen MA, Puri V, Meyers BF, Kozower BD. Current state of empyema management. *Ann Thorac Surg.* 2018;105:1589-96. doi: 10.1016/j.athoracsur.2018.02.027
27. Slaats M, Dooy JD, Lauwers P, Van Schil P, Verhulst S, Hendriks J. Intrapleural use of dornase alfa and tissue plasminogen activator are successful as treatment in pediatric empyema: a pilot study. *Eur Resp J[Internet]* 2018[cited 2024 Jan 8];52(62): PA4635. Available from: https://erj.ersjournals.com/content/52/suppl_62/PA4635 doi: 10.1183/13993003.congress-2018.PA4635
28. Tawfek A, Elsharawy M, Ibrahim M, Mansour A. Results of two fibrinolytics in treatment of the early stage of empyema. *Zagazig University Med J.* 2022;29(1):120-6. doi: 10.21608/zumj.2022.153200.2611
29. Hendaus MA, Abushahin A. Intrapleural hemorrhage due to alteplase use in a 6-year-old boy with pleural effusion. *Int J Gen Med.* 2013;6:233-6. doi: 10.2147/IJGM.S43783
30. Altmann ES, Crossingham I, Wilson S, Davies HR. Intra-pleural fibrinolytic therapy versus placebo, or a different fibrinolytic agent, in the treatment of adult parapneumonic effusions and empyema. *Cochrane Database of Syst Rev[Internet]*. 2019[cited 2024 Jan 8];10: CD002312. Available from: <https://www.cochranelibrary.com/cdsr/doi/10.1002/14651858.CD002312.pub4/full> doi: 10.1002/14651858
31. Pogorelic Z, Bjelanovic D, Gudelj R, Jukic M, Petric J, Furlan D. Video-assisted thoracic surgery in early stage of pediatric pleural empyema improves outcome. *Thor Cardiovasc Surg.* 2021;69(5):475-80. doi:10.1055/s-0040-1708475
32. Saxena K, Maturu VN. A comparative study of the safety and efficacy of intrapleural fibrinolysis with streptokinase and urokinase in the management of loculated pleural effusions. *Cureus[Internet]*. 2022[cited 2024 Feb 1]14(6): e26271. Available from: <https://www.ncbi.nlm.nih.gov/pmc/articles/PMC9308892/> doi: 10.7759/cureus.26271
33. Chan DT, Sihoe AD, Chan S, Tsang DS, Fang B, Lee TW, et al. Surgical treatment for empyema thoracis: is video-assisted thoracic surgery «better» than thoracotomy? *Ann Thorac Surg.* 2007;84(1):225-31. doi: 10.1016/j.athoracsur.2007.03.019
34. Sanghvi Y, Kewlani R, Walawalkar A, Kamat N, Birajdar S. Video-assisted thoracoscopic Surgery (VATS) in a 20-day-old newborn with empyema thoracis. *Indian Pediatr.* 2021;58(3):284-5.
35. Jain M, Jain P, Mehta AP, Sikka G, Sidana P. Empyema thoracis in a neonate. *J Paediatr Neonatal Med[Internet]*. 2020[cited 2024 Feb 1];2(2):119. Available from: https://www.researchgate.net/profile/Mayank-Jain-40/publication/343386091_Empyema_Thoracis_in_a_Neonate/links/5f270dc4458515b729fe3413/Empyema-Thoracis-in-a-Neonate.pdf

ВИДЕОАСИСТОВАНА ТОРАКОСКОПІЧНА ОПЕРАЦІЯ У 35-ДЕННОГО НЕМОВЛЯТИ З МУЛЬТИЛОКАЛІЗОВАНОЮ ЕМПІЄМОЮ ПЛЕВРАЛЬНОЇ ПОРОЖНИНИ: КЛІНІЧНИЙ ВИПАДОК

С. Бабуці, В. Негру, І. Амброш, І. Ревенко, Д. Хайдарлі

Інститут матері та дитини (Кишинів, Республіка Молдова),
 Національний науково-практичний центр дитячої хірургії «Наталія Георгіу»
 (Кишинів, Республіка Молдова),
 Державний університет медицини і фармації «Ніколає Тестеміцану»
 (Кишинів, Республіка Молдова)

Резюме.

Автори повідомляють про клінічний випадок мультилокалізованої емпієми плевральної порожнини у 35-денної дитини, з приводу чого вона була успішно прооперована. Немовля було переведено з регіонального медичного закладу з лихоманкою, малопродуктивним кашлем і задишкою. Захворювання почалося 7 днів тому, але, незважаючи на 5 днів лікування антибіотиками в лікарні за місцем проживання, стан дитини продовжував погіршуватися, з приводу чого його перевели в дитяче відділення інтенсивної терапії нашого закладу. Після госпіталізації на КТ виявлено масивні закриті рідинні скупчення з субплевральною локалізацією у правій плевральній порожнині та у проекції переднього середостіння, що супроводжувались субтотальним ателектазом правої легені, плевритом без ознак деструкції легеневої тканини та підозрою на кістозну лімфангіому легені. Пацієнту було виконано відеоасистовану торакоскопічну операцію (ВАТО), під час якої було виявлено декілька гнійних локалізованих скупчень, що були розкриті та дреновані з отриманням близько 200 мл в'язкої гнійної рідини. Післяопераційний період був складним, але сприятливим. Через 6 місяців КТ і сцинтиграфія показали незначні залишкові зміни в легенях і дифузні перфузійні зміни, що підтверджують повільну регресію септичного запального процесу в плевральній порожнині після розршення. Автори роблять висновок, що представлений випадок висвітлює труднощі візуалізаційної диференціальної діагностики і свідчить про те, що ВАТО є ефективним і безпечним методом лікування немовлят з емпіємою плеври, особливо при мультилокальних фібринозно-гнійних формах, що дозволяє досягти сприятливого результату з короткою тривалістю торакостомії з трубкою і порівняно коротким періодом одужання та госпіталізації.

Ключові слова: мультилокалізована емпієма; плевра; легеня; ВАТО; немовля.

Contact information:

Stanislav Babuci – MD, PhD, DSc., Head of National Scientific-Practical Center for Pediatric Surgery «Natalia Gheorghiu», Mother and Child Institute (Kishinev, Republic of Moldova)

e-mail: babucistanislav1@gmail.com

ORCID ID: <https://orcid.org/0000-0002-1153-4871>

Virginia Negru – MD, Pediatric Surgeon, National Scientific-Practical Center for Pediatric Surgery «Natalia Gheorghiu», Mother and Child Institute (Kishinev, Republic of Moldova)

e-mail: virginia.munteanu.m@gmail.com

ORCID ID: <https://orcid.org/0009-0000-1934-3327>

Igor Ambros – MD, Pediatric Surgeon, National Scientific-Practical Center for Pediatric Surgery «Natalia Gheorghiu», Mother and Child Institute (Kishinev, Republic of Moldova)

e-mail: igorambros2000@yahoo.com

ORCID ID: <https://orcid.org/0000-0001-9194-9032>

Ina Revenco – MD, PhD, Pediatric Surgeon, National Scientific-Practical Center for Pediatric Surgery «Natalia Gheorghiu», Mother and Child Institute (Kishinev, Republic of Moldova)

e-mail: ina.revenco@yahoo.com

ORCID ID: <https://orcid.org/0000-0001-4976-0863>

Doina Haidarli – MD, Pediatric Surgeon, National Scientific-Practical Center for Pediatric Surgery «Natalia Gheorghiu», Mother and Child Institute (Kishinev, Republic of Moldova) e-mail: doina.haidarli@inbox.ru

ORCID ID: <https://orcid.org/0000-0001-8604-4669>

Контактна інформація:

Бабуці Станіслав – д.мед.н., керівник Національного науково-практичного центру дитячої хірургії ім. Наталії Георгіу, Інститут матері та дитини (Кишинів, Республіка Молдова)

e-mail: babucistanislav1@gmail.com

ORCID ID: <https://orcid.org/0000-0002-1153-4871>

Негру Вірджинія – д.мед.н., дитячий хірург, Національний науково-практичний центр дитячої хірургії імені Наталії Георгіу, Інститут матері і дитини (Кишинів, Республіка Молдова)

e-mail: virginia.munteanu.m@gmail.com

ORCID ID: <https://orcid.org/0009-0000-1934-3327>

Амброш Ігор – д.мед.н., дитячий хірург, Національний науково-практичний центр дитячої хірургії імені Наталії Георгіу, Інститут матері та дитини (Кишинів, Республіка Молдова)

e-mail: igorambros2000@yahoo.com

ORCID ID: <https://orcid.org/0000-0001-9194-9032>

Ревенко Іна – д.мед.н., дитячий хірург, Національний науково-практичний центр дитячої хірургії імені Наталії Георгіу, Інститут матері та дитини (Кишинів, Республіка Молдова)

e-mail: ina.revenco@yahoo.com

ORCID ID: <https://orcid.org/0000-0001-4976-0863>

Хайдарлі Дойна – д.мед.н., дитячий хірург, Національний науково-практичний центр дитячої хірургії імені Наталії Георгіу, Інститут матері та дитини (Кишинів, Республіка Молдова) e-mail: doina.haidarli@inbox.ru

ORCID ID: <https://orcid.org/0000-0001-8604-4669>



Received for editorial office on 10/02/2024

Signed for printing on 15/04/2024