

ВИПАДКИ З ПРАКТИКИ

UDC: 616.24-053.2-006.2-089

DOI: 10.24061/2413-4260.XIII.3.49.2023.16

S. Babuci^{1,2}, *N. Dogotari*¹, *V. Petrovici*^{1,2},
*I. Negru*¹, *V. Negru*²

Public Medical-Sanitary Institution Mother and Child
Institute "Natalia Gheorghiu" National Scientific-
Practical Center for Pediatric Surgery¹,
"Nicolae Testemițanu" State University of Medicine and
Pharmacy² (Chisinau, Moldova)

PARENCHYMA PRESERVING SURGERY IN THE MANAGEMENT OF GIANT PULMONARY HYDATID CYST COMPLICATED BY ENDOBRONCHIAL RUPTURE IN CHILDREN: CASE REPORT

Summary

The authors report a clinical case of a 15-year-old female patient with a giant pulmonary hydatid cyst that was diagnosed only after rupture and successfully operated. The patient suffered a minor trauma during gym class, and a short time after the trauma she vomited profusely with a large amount of colorless fluid. Subsequently, her condition worsened, with fatigue, severe pain in the right hemithorax, severe cough with poor sputum, dyspnea and unspoken hemoptysis, so she was admitted to the hospital. After admission, a CT scan confirmed the diagnosis of pulmonary hydatid cyst complicated by endobronchial rupture with subtotal involvement of the right lower lobe. The patient underwent surgery by right lateroposterior thoracotomy. After removal of the parasitic larvocyst, the remaining postechinococectomy cavity was padded. In the postoperative period, partial insufficiency of the padding sutures was observed, which was treated conservatively.

The authors conclude that echinococectomy with silver nitrate treatment of the residual cavity and filling with superimposed bursae in giant pulmonary hydatid cyst complicated by endobronchial rupture is an effective technical procedure that allows to reduce postoperative morbidity and hospitalization time in this serious complication.

Key words: Hydatid cyst; Lung; Protoscolycidal Agent; Surgery; Child.

Hydatidosis is a worldwide public health problem characterized by significant postoperative morbidity and mortality in endemic areas, including children [1, 2]. The negative intrathoracic pressure combined with the high elasticity of the lung parenchyma in children and adolescents, against the background of a not fully developed immune system, causes the rapid asymptomatic growth of hydatid metacestode to impressive sizes [3, 4]. Although there is no standard size to define a traditional "giant" hydatid cyst, parasitic cystic formations with a diameter greater than 10 cm are considered giant hydatid cysts, which represent a special clinical entity in children, determined by some technical difficulties of surgical treatment, which often requires lung resection and is often associated with postoperative complications, which significantly prolong the hospital stay and increase costs [5, 6]. At the same time, giant lung cysts are likely to be complicated by rupture, endangering the life of the child [7]. In this context, we report a clinical case of a patient with a giant pulmonary hydatid cyst that was diagnosed after rupture and successfully operated.

Patient C., 15 years old, was urgently hospitalized in our institution by air ambulance, the patient suffered an insignificant trauma during physical education. At the time of admission, the patient's condition was serious, with fatigue, severe pain in the right hemithorax, severe cough with poor expectoration, dyspnea and mild hemoptysis. About 4 hours ago, after a short period of time from the trauma of being hit with the ball, she vomited profusely with a large amount of colorless liquid. Heredocollateral antecedents were insignificant.

General examination revealed a normosthenic constitution, significantly reduced excursion of the right

hemithorax, auscultatory breathing only in the apical regions on the right side, contralateral ragged breathing. Pulse – 95-100 beats/min, blood pressure – 90/60. Routine laboratory tests showed leukocytosis (18.2x10⁹), increased ESR.

The chest x-ray showed a large cystic formation located in the middle and lower lung with a well-defined internal contour, with a horizontal hydro-aerial plane, the external contour being obliterated; massive perifocal pneumonic infiltration and areas of pneumofibrosis (Fig. 1). Computed tomography allowed to establish with certainty the diagnosis of pulmonary hydatid cyst complicated by endobronchial rupture with subtotal involvement of the right lower lobe (Fig. 2).

In the projection of the lower lobe of the right lung, a solitary massive hydroaerial cystic formation, well outlined, with dimensions of 10.3x8.0x9.0 cm is visualized. The floating membrane sign („Camelot sign") is clearly highlighted. On the posterior wall of the cavity, the presence of some linear structures with a tortuous path determined by the collapse of the hydatid larvocyst can be observed. There is hyperattenuation of the adjacent lung parenchyma determined by consolidation with involvement of the lower and middle lobe on the right. Pleural effusion is present on the right (18-20 UH) with a maximum thickness of 4.0 cm.

After preoperative preparation, a right lateral posterior thoracotomy was performed. During the revision, a cystic formation of large dimensions was found, occupying almost the entire lower lobe, with significant compression of the adjacent lung segments and the middle lobe. After opening the formation, the ruptured hydatid larvocyst was found, which had a thin wall and was floating in a small residual amount of hydatid fluid (Fig. 3).

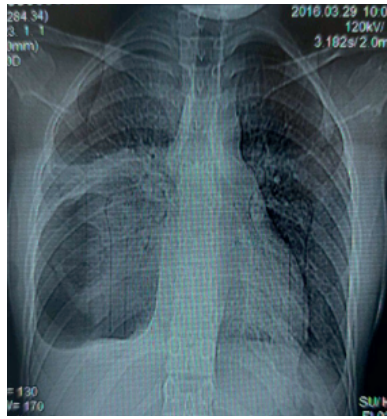


Fig. 1. Patient C., 15 years old. Preoperative chest X-ray (explanation in text)

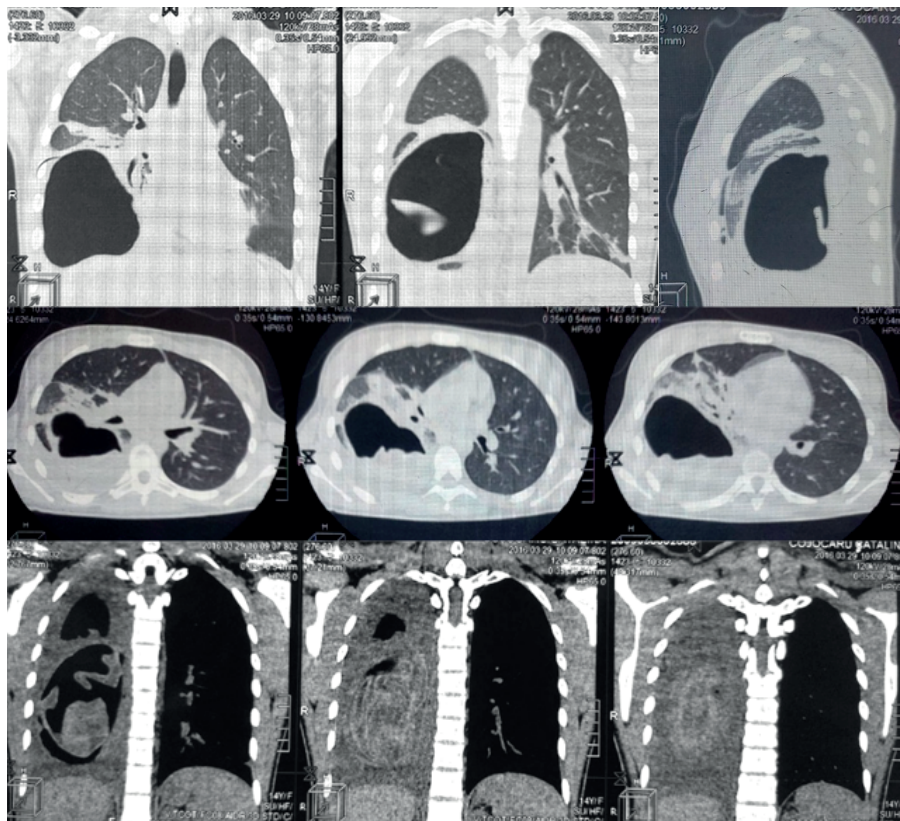


Fig. 2. Patient C., 15 years old. Preoperative CT.

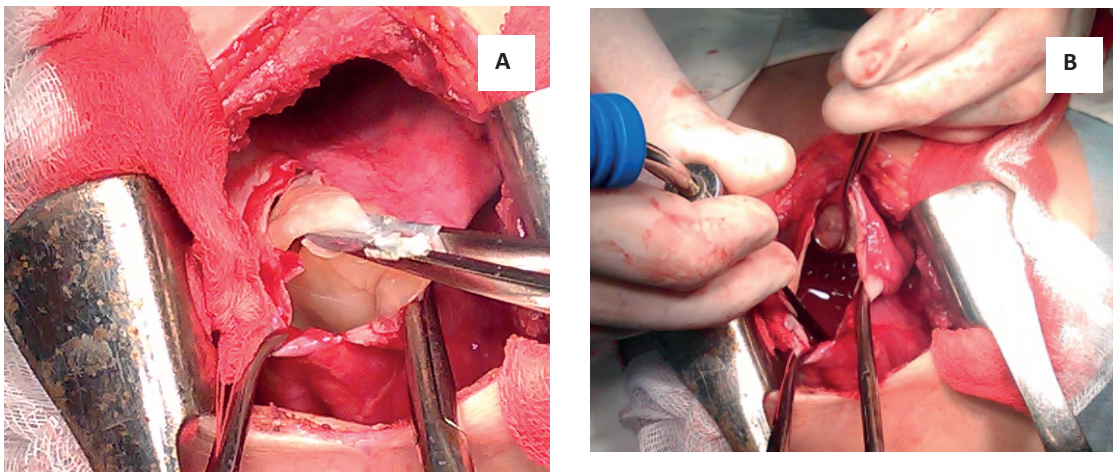


Fig. 3. Intraoperative appearance of pulmonary hydatid larvocyst complicated by endobronchial rupture after opening the fibrous capsule (A) and after removal of the parasitic agent (B)

After extraction of the parasitic formation and aspiration of the fluid content, a bronchial communication of about 3-4 mm in diameter was observed. The residual cavity was treated with silver nitrate as a scolicial agent, after which the bronchial fistula was liquidated. After placement of an intracavitary drain, the residual cavity was filled post-technocoectomy by suturing through meridional puncture in the superimposed bursae plan-on-plan with absorbable wires and a final “round-trip” suture, completing the operation with drainage of the pleural cavity and restoration

of the anatomical plan. The intrapleural drain was removed on postoperative day 5, and the patient was discharged in satisfactory general condition on postoperative day 14.

In the postoperative period, the partial insufficiency of the padding sutures was associated (Fig. 4A, B), the intracavitary drain being removed 3.2 months postoperatively. However, the development of serious complications, which would have required some surgical interventions, was not noticed, the remaining cavity gradually disappearing completely (Fig. 4C, D, E, F).

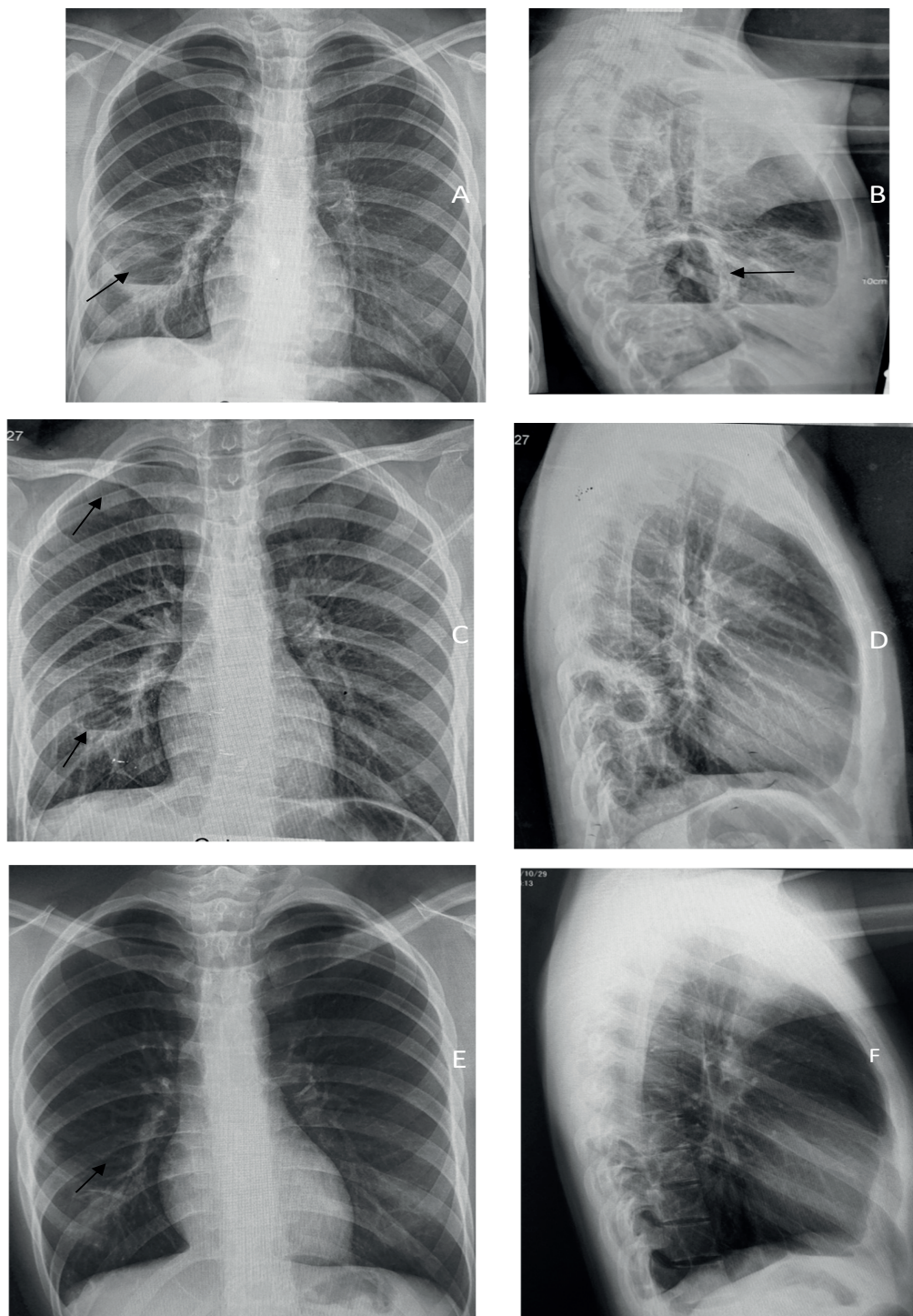


Fig. 4. Patient C., 15 years old. Chest X-ray in 2 incidences (right profile) taken 1.2 months (A, B), 3.4 months (C, D), and 12 months (E, F) from the time of surgery. The presence of a small cavity with drained hydro-aerial content, located in the lower lobe of the right lung, is determined, which gradually decreases in size until it disappears completely

The morphopathological examination revealed complicated necrotic and proliferative changes with suppurative erosive-ulcerative lesions in the fibrous capsule, associated with pseudofollicular

and perivascular inflammatory reaction, cystic reorganization of the bronchiolo-alveolar component with proliferative-polypous alveolitis of the pericyclic lung tissue (Fig. 5).

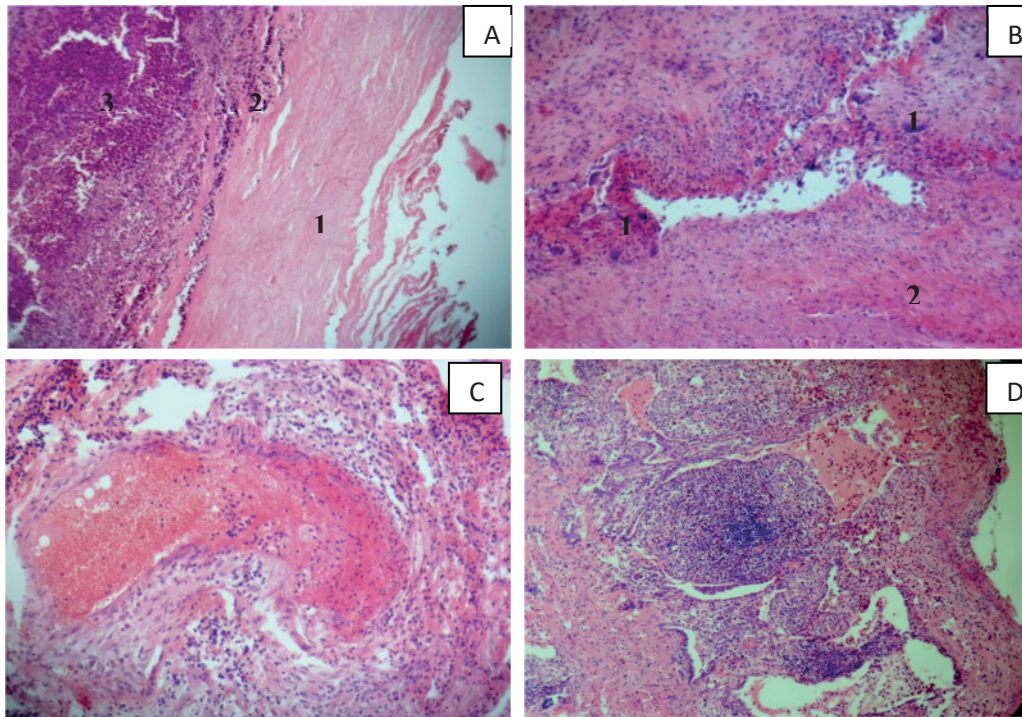


Fig. 5. Morphopathological changes of the fibrous capsule and pericyclic lung tissue.

A – histopathological aspects of the fibrous capsule: 1 – ischemic changes and disjunction of the fibrous capsule; 2 – penetration of the polymorphocellular inflammatory process with an eosinophilic component into the fibrous capsule; 3 – destructive inflammatory process in the pericyclic regional area;
B – bronchogenic inflammatory process: 1 – ulcerative erosive inflammatory process with giant cell symplasts; 2 – fibro-muscular and connective tissue;
C – increasing parietal vascular thrombosis;
D – Reminiscences of cystic deformed intracapsular bronchoalveolar structures with granular polyp structures

Discussions. Giant pulmonary hydatid cyst in children represents a special clinical entity, characterized by delayed onset of clinical symptoms due to high elasticity and compliance of the lung [1], which determines the expansion of the parasitic formation, the rupture of the parasitic larvovest contributes to the development of serious consequences [5, 8]. The incidence of pulmonary hydatid cyst complicated by rupture is 34.2-39.5% [9].

Modern imaging techniques are quite effective in the diagnosis of pulmonary hydatid cyst. At the same time, in giant forms and those complicated by rupture, the radiological diagnosis of empyema or hydrothorax is often incorrect, but it is precisely in these forms of the disease that the need for prompt surgical treatment as soon as possible after stabilization of the patient is imposed, with the aim of removing the hydatid larvovest with maximum preservation of lung tissue [6, 10].

Among the options for surgical treatment of large pulmonary hydatid cysts, the Barrett/Posadas technique, which consists of cystotomy with closure of bronchopleural fistulas with or without padding, has been widely used [11]. Cystotomy with padding involves aspiration of fluid from the cyst together with removal of the parasitic larvovest,

padding of the residual cavity contributes to the reduction of the risk of infection of the residual cavity and formation of empyema, liquidation of air leaks from the airways with the risk of deformation of the lung parenchyma [12, 13], in this context some modifications of the padding technique have been proposed [14]. It should be noted that the Ugon enucleation technique, which is a surgical procedure that allows the removal of the intact parasitic cyst, can be used primarily in small hydatid cysts with a low risk of rupture [15]. The method of solving the residual cavity without padding may be an alternative to the padding procedure in cases of pulmonary hydatid cyst; proponents of this method claim that padding is not essential in the surgical treatment of pulmonary hydatid cysts, and careful closure of the bronchial orifices should reduce morbidity [16, 17].

Some authors have suggested to perform lung resection in cases of giant pulmonary hydatid cysts as a last option, the rate of these interventions is 6-13% [18, 19]. Some studies have adopted specific criteria for lung resection, such as: severe hemorrhage in the hydatid cyst complicated by rupture, giant pulmonary hydatid cysts with a destructive process exceeding 50% of a lung lobe, suppuration of the cystic cavity, concomitant aspiration with lobe stiffness [19].

Taking into account the high capacity of lung tissue recovery in children, there is a contrary opinion, which suggests that this type of surgery should be avoided, which has high rates of postoperative complications, including: postoperative wound infection (19.4%), pneumonia (11.1%), atelectasis (8.3%), empyema (8.3%), prolonged air leaks (5.5%), etc. [20].

Although surgical procedures have shown satisfactory results in the treatment of hydatid cysts, there is a risk of developing secondary infections, with recurrence rates ranging from 2 to 25% of patients. In this context, particular attention has been paid to scolical agents used for intraoperative inactivation of the germinal elements of the hydatid larvocyst and determination of the effective exposure time [21, 22]. In addition to the scolical substances known and used in practice [21], several recent studies have reported, as an alternative option, the use of scolical agents of plant origin [23, 24], nanoparticles of silver, iron, copper, selenium, etc. [25, 26], the venom peptides of some scorpion species [27, 28], although the results obtained are still in the stage of desideratum.

Conclusions:

1. Filling of the post-technococectomy residual cavity in superimposed bursae in giant pulmonary hydatid

cyst complicated by endobronchial rupture is an effective technical procedure that allows to reduce postoperative morbidity and length of hospitalization..

2. The morphopathologic changes found in the giant pulmonary hydatid cyst complicated with endobronchial rupture indicate a potential risk of development of insufficiency of padding sutures with development of prolonged air leaks. In this context, with the aim of monitoring and resolving prolonged air leaks that may occur in the postoperative period, the padding procedure can be completed with simultaneous drainage of the residual cavity..

3. The intraoperative use of silver nitrate as an attempt to inactivate the germinal elements of the hydatid larvocyst is based on both the scolical and bactericidal action of the substance, which, together with the necrolytic action, ensures favorable conditions for the obliteration of the residual cavity of the post-technococectomy and contributes to the prevention of recurrences and postoperative complications.

Conflict of interest: none.

Source of financing: personal funds.

References:

1. Dogru MV, Sezen CB, Aker C, Erdogu V, Erduhan S, Cansever L, et al. Evaluating Giant Hydatid Cysts: Factors Affecting Mortality and Morbidity. *Ann Thorac Cardiovasc Surg.* 2021;27(3):164-8. doi: 10.5761/atcs.0a.20-00178
2. Goussard P, Eber E, Mfingwana L, Nel P, Schubert P, Janson J, et al. Paediatric pulmonary echinococcosis: A neglected disease. *Paediatr Respir Rev.* 2022;43:11-23. doi: 10.1016/j.prrv.2021.11.001
3. Sokouti M, Shokouhi B, Sokouti M, Sokouti B. Giant Pulmonary Hydatid Cyst and Trauma in a 9 Year-Old Child: A Case Report. *Open Respir Med J.* 2015;9:67-9. doi: 10.2174/1874306401509010067
4. Kocaman OH, Günendi T, Dere O, Dörterler ME, Boleken ME. Pulmonary Hydatid Cyst in Children: A Single-Institution Experience. *Cureus [Internet].* 2022[cited 2023 Aug 11];14(7): e26670. Available from: <https://www.ncbi.nlm.nih.gov/pmc/articles/PMC9357973/pdf/cureus-0014-00000026670.pdf> doi: 10.7759/cureus.26670
5. Aqqad A, Hamdi B, Louhaichi S, Khalfallah I, Attia M, Zairi S, et al. Giant pulmonary hydatid cyst in children. *Arch Pediatr.* 2021;28(4):273-7. doi: 10.1016/j.arcped.2021.02.017
6. Khalfallah I, Hajjej S, Ferchichi M, Boussetta A, Affes M, Louhaichi S, et al. Giant pulmonary hydatid cyst in children. *Monaldi Arch Chest Dis [Internet].* 2021[cited 2023 Aug 11];92(1). Available from: <https://www.monaldi-archives.org/index.php/macd/article/view/1770> doi: 10.4081/monaldi.2021.1770
7. Mahmudlou R, Roydel F, Rivaz B, Moradi M, Khalilpour A, Mobarak K, et al. Traumatic rupture of a latent lung hydatid cyst and drowning and asphyxia with hydatid fluid in a 5-year-old boy, 2021: a case report. *Stud. Med. Sci.* 2021;32(9):684-90.
8. Ataya J, Hanifa H, Ismail A, Ismail A. Ruptured hydatid cyst presenting with a hydropneumothorax in a 16-year-old boy: A case report from Syria. *Int J Surg Case Rep [Internet].* 2023[cited 2023 Aug 11];105:108034. Available from: <https://www.sciencedirect.com/science/article/pii/S2210261223001621/pdf?md5=738b97f7f23a1aa4da23263603f68108&pid=1-s2.0-S2210261223001621-main.pdf> doi: 10.1016/j.ijscr.2023.108034
9. Hamouri S, Odat H, Syaj S, Hecker E, Alrabadi N. Rupture of pulmonary hydatid cyst in pediatrics: A cross-sectional study. *Ann Med Surg (Lond).* 2021;62:31-6. doi: 10.1016/j.amsu.2021.01.001
10. Karamustafaoglu YA, Gungor A. Traumatic rupture of giant pulmonary hydatid cyst in children. *Hong Kong J Emerg Med.* 2010;17(4):381-3. doi: 10.1177/102490791001700413
11. Amirian A, Ziaian B, Erfani A, Shahriarirad R, Ranjbar K. Successful Management of a Huge Pulmonary Hydatid Cyst with Lung-Preserving Surgery. *Case Rep Surg [Internet].* 2020[cited 2023 Aug 11];2020:9526406. Available from: <https://www.hindawi.com/journals/cris/2020/9526406/> doi: 10.1155/2020/9526406
12. Nabi MS, Waseem T. Pulmonary hydatid disease: what is the optimal surgical strategy? *Int J Surg.* 2010;8(8):612-6. doi: 10.1016/j.ijssu.2010.08.002
13. Ksia A, Fredj MB, Zouaoui A, Kechiche N, Belhassen S, Mosbahi S, et al. Capitonage seems better in childhood pulmonary hydatid cyst surgery. *J Pediatr Surg.* 2020;55(4):752-5. doi: 10.1016/j.jpedsurg.2019.05.009
14. Aydin Y, Ulas AB, Ince I, Kuran E, Keskin H, Kirimli SN, et al. Modified capitonage technique for giant pulmonary hydatid cyst surgery. *Interact Cardiovasc Thorac Surg.* 2021;33(5):721-6. doi: 10.1093/icvts/ivab152
15. Rawat S, Kumar R, Raja J, Singh RS, Thingnam SKS. Pulmonary hydatid cyst: Review of literature. *J Family Med Prim Care.* 2019;8(9):2774-8. doi: 10.4103/jfmpc.jfmpc_624_19
16. Turna A, Yilmaz MA, Hacıbrahimoglu G, Kutlu CA, Bedirhan MA. Surgical treatment of pulmonary hydatid cysts: is capitonage necessary? *Ann Thorac Surg.* 2002;74(1):191-5. doi: 10.1016/s0003-4975(02)03643-3
17. Eren MN, Balci AE, Eren S. Non-capitonage method for surgical treatment of lung hydatid cysts. *Asian Cardiovasc Thorac Ann.* 2005;13(1):20-3. doi: 10.1177/021849230501300105

18. Arroud M, Afifi MA, El Ghazi K, Nejari C, Bouabdallah Y. Lung hydatid cysts in children: comparison study between giant and non-giant cysts. *Pediatr Surg Int.* 2009;25(1):37-40. doi: 10.1007/s00383-008-2256-z
19. Sokouti M, Pezeshkian M, Ghabili K, Ej Golzari S. Surgical procedures and postoperative complications in patients with giant and non-giant pulmonary hydatid cysts. *Life Sci. J.* 2013;10:138-42.
20. Onal O, Demir OF. Is Anatomic Lung Resection Necessary in Surgical Treatment of Giant Lung Hydatid Cysts in Childhood? *Ann Thorac Cardiovasc Surg.* 2017;23(6):286-90. doi: 10.5761/atcs.0a.17-00023
21. Fakharzadeh Jahromi K, Rafiei A, Rahdar M, Bahreini A. Evaluation of the Protoscolicidal Effectiveness of Hypertonic Saline, Silver Nitrate, Ethanol, Using Sponge Pad Method and Injecting into Fertile Hydatid Cysts. *Iran J Parasitol.* 2022;17(2):223-30. doi: 10.18502/ijpa.v17i2.9540
22. Sharafi SM, Sefiddashti RR, Sanei B, Yousefi M, Darani HY. Scolicidal agents for protoscolices of *Echinococcus granulosus* hydatid cyst: Review of literature. *J Res Med Sci [Internet].* 2017[cited 2023 Aug 11];22:92. Available from: https://journals.lww.com/jrms/fulltext/2017/22000/scolicidal_agents_for_protoscolices_of.92.aspx doi: 10.4103/jrms.JRMS_1030_16
23. Almohammed HI, Alkhaibari AM, Alanazi AD. Antiparasitic effects of *Elettaria cardamomum* L. essential oil and its main compounds, 1-8 Cineole alone and in combination with albendazole against *Echinococcus granulosus* protoscolices. *Saudi J Biol Sci.* 2022;29(4):2811-8. doi: 10.1016/j.sjbs.2022.01.005
24. Rahimi-Esboei B, Ebrahimzadeh MA, Fathi H, Rezaei Anzahaie F. Scolicidal effect of *Allium sativum* flowers on hydatid cyst protoscolices. *Eur Rev Med Pharmacol Sci.* 2016;20(1):129-32.
25. Norouzi R, Ataei A, Hejazy M, Noreddin A, El Zowalaty ME. Scolicidal Effects of Nanoparticles Against Hydatid Cyst Protoscolices in vitro. *Int J Nanomedicine.* 2020;15:1095-100. doi: 10.2147/IJN.S228538
26. Nematollahi A, Shahbazi P, Rafat A, Ghanbarlu M. Comparative survey on scolicidal effects of selenium and silver nanoparticles on protoscolices of hydatid cyst. *Open Vet J.* 2018;8(4):374-7. doi: 10.4314/ovj.v8i4.4
27. Jafari H, Nemati M, Haddad Molayan P, Khaleghi Rostamkolaie L, Hamidi Nejat H. Scolicidal activity of *Mesobuthus eupeus* venom against the protoscolices of *Echinococcus granulosus*. *Arch Razi Inst.* 2019;74(2):183-9. doi: 10.22092/ari.2018.121416.1213
28. Al-Malki ES, Abdelsater N. In vitro Scolicidal effects of *Androctonus crassicauda* (Olivier, 1807) venom against the protoscolices of *Echinococcus granulosus*. *Saudi J Biol Sci.* 2020;27(7):1760-5. doi: 10.1016/j.sjbs.2020.05.014

ПАРЕНХИМОЗБЕРІГАЮЧА ХІРУРГІЯ ПРИ ЛІКУВАННІ ГІГАНТСЬКОЇ ГІДАТИДНОЇ КІСТИ ЛЕГЕНІ, УСКЛАДНЕНОЇ ЕНДОБРОНХІАЛЬНИМ РОЗРИВОМ У ДІТЕЙ: КЛІНІЧНИЙ ВИПАДОК

С. Бабуці^{1,2}, Н. Доготарі¹, В. Петровіч^{1,2}, І. Незру¹, В. Незру²

Комунальний медико-санітарний заклад Інститут матері та дитини
Національний науково-практичний центр дитячої хірургії «Наталія Георгіу»¹,
Державний університет медицини та фармації «Ніколае Тестеміцану»²
(м. Кишинів, Молдова)

Резюме

Автори повідомляють про клінічний випадок 15-річної пацієнтки з гігантською легеневою гідатидною кістою, яка була діагностована лише після розриву, та успішно прооперована. Пацієнтка отримала легку травму під час заняття фізкультурою і через короткий час після травми у неї виникла сильна рвота великою кількістю безбарвної рідини. Згодом її стан погіршився, з'явилися втома, сильний біль у правій половині грудей, сильний кашель з незначним харкотинням, задишка та кровохаркання, у зв'язку з чим її госпіталізували. Після госпіталізації комп'ютерна томографія (КТ) підтвердила діагноз гідатидної кісти легені, ускладненої ендобронхіальним розривом із субтотальним ураженням правої нижньої частки. Хвора прооперована шляхом правосторонньої латерозадньої торакотомії. Після видалення паразитарної ларвоцисти решту постехінококкетомічної порожнини заповнили. У післяопераційному періоді спостерігалася часткова неспроможність накладних швів, яку лікували консервативно.

Автори дійшли висновку, що ехінококкетомія з обробкою нітратом срібла залишкової порожнини та заповненням накладеними бурсами при гігантській легеневій гідатидній кісті, ускладненій ендобронхіальним розривом, є ефективним технічним втручанням, яке дозволяє скоротити післяопераційну захворюваність і терміни госпіталізації при цьому тяжкому ускладненні.

Ключові слова: гідатидна кіста; легеня; протосколіцидний засіб; хірургія; дитина.

Contact information:

Stanislav Babuci – MD, PhD, DSc., Head of “Natalia Gheorghiu” National Scientific-Practical Center for Pediatric Surgery, PMSI Mother and Child Institute, “Nicolae Testemitanu” State University of Medicine and Pharmacy (Chisinau, Moldova).
e-mail: babucistanislav1@gmail.com
ORCID ID: <https://orcid.org/0000-0002-1153-4871>

Nicolae Dogotari – MD, Head of Emergency Reception Unit, PMSI Mother and Child Institute (Chisinau, Moldova).
e-mail: dogotaricolae17@gmail.com
ORCID ID: <https://orcid.org/0009-0002-8672-8897>

Контактна інформація:

Бабуці Станіслав – MD, PhD, DSc., керівник Національного науково-практичного центру дитячої хірургії «Наталія Георгіу», Комунальний медико-санітарний заклад Інститут матері та дитини, Державний університет медицини та фармації «Ніколае Тестеміцану» (Кишинев, Молдова).
e-mail: babucistanislav1@gmail.com
ORCID ID: <https://orcid.org/0000-0002-1153-4871>

Доготарі Ніколае – MD, керівник відділення невідкладної допомоги Комунального медико-санітарного закладу Інститут матері та дитини (Кишинев, Молдова).
e-mail: dogotaricolae17@gmail.com
ORCID ID: <https://orcid.org/0009-0002-8672-8897>

Vergil Petrovici – MD, PhD, Head of the Pathological Anatomy Department of PMSI Mother and Child Institute, “Nicolae Testemițanu” State University of Medicine and Pharmacy (Chisinau, Moldova).

e-mail: petrovicivergil@yahoo.com

ORCID ID: <https://orcid.org/0000-0001-8352-4202>

Ion Negru – MD, PhD, Head of the Septic Surgery Department of “Natalia Gheorghiu” National Scientific-Practical Center for Pediatric Surgery, PMSI Mother and Child Institute (Chisinau, Moldova).

e-mail: ionnegru@yahoo.com

ORCID ID: <https://orcid.org/0000-0002-6758-3613>

Virginia Negru – Resident Doctor of Pediatric Surgery, “Nicolae Testemițanu” State University of Medicine and Pharmacy, PMSI Mother and Child Institute (Chisinau, Moldova).

e-mail: virginia.munteanu.m@gmail.com

ORCID ID: <https://orcid.org/0009-0000-1934-3327>

Петровичі Вергіл – MD, завідувач кафедри патологічної анатомії Комунального медико-санітарного закладу Інститут матері та дитини, Державний університет медицини та фармації «Ніколае Тестеміцану» (Кишинев, Молдова).

e-mail: petrovicivergil@yahoo.com

ORCID ID: <https://orcid.org/0000-0001-8352-4202>

Негру Іон – MD, завідувач відділенням септичної хірургії Національного науково-практичного центру дитячої хірургії «Наталія Георгіу», Комунальний медико-санітарний заклад Інститут матері та дитини (Кишинів, Молдова).

e-mail: ionnegru@yahoo.com

ORCID ID: <https://orcid.org/0000-0002-6758-3613>

Негру Вірджинія – лікар-ординатор дитячої хірургії, Державний університет медицини та фармації «Ніколае Тестеміцану», Комунальний медико-санітарний заклад Інститут матері та дитини (Кишинев, Молдова).

e-mail: virginia.munteanu.m@gmail.com

ORCID ID: <https://orcid.org/0009-0000-1934-3327>

Received for editorial office on 10/05/2023

Signed for printing on 15/08/2023

