

UDC: 618.18-053.2-06-089.844

DOI: 10.24061/2413-4260.XIII.3.49.2023.8

RESULTS OF SURGICAL CORRECTION  
OF POSTOPERATIVE COMPLICATIONS IN  
ANORECTAL MALFORMATION IN CHILDREN*A. Zh. Khamraev, D. B. Rakhmonov,  
U. A. Khamroev*Tashkent Pediatric Medical Institute, Samarkand State  
Medical University (Tashkent, Republic of Uzbekistan)**Summary**

*The high frequency of postoperative complications (POC) in the anorectal zone remains an urgent problem of pediatric surgery. Satisfactory results after a single intervention are 50-80%. After the correction of anorectal postoperative malformation (APM), functional disorders of the sphincter apparatus of the rectum are observed in 30-60% of patients, which further leads to fecal incontinence (FI) and chronic constipation (CC). We retrospectively analyzed the causes of the most common recurrent pathological conditions in the anorectal zone in children as well as tactical approaches, methods of software correction, and considered ways to prevent them.*

*The aim. The goal is to improve the results of surgical correction of postoperative complications (POC) in the anorectal zone in children.*

*Material and methods. 78 patients with POC in the anorectal zone after primary and repeated correction of anorectal malformations (ARM) were examined. 197 reconstructive operations were performed. The diagnostic algorithm consisted of clinical, X-ray, laboratory examination, MRI and endoscopic examination methods.*

*The study has been carried out in accordance with the principles of the Helsinki Declaration. The research protocol was approved by the Local Ethics Committee (LEK) of all participating institutions. The informed consent of the children's parents was obtained for the research. The authors declare that there is no conflict of interest.*

*Statistical processing of the study results was carried out using standard methods with the calculation of the absolute number of observations (n) and the percentage ratio (%).*

*Results and discussion. The analysis of long-term results after the primary and repeated correction of the ARM showed that unreliable primary diagnosis, inadequate preoperative preparation, and the choice of the operation method led to the development of postoperative anal sphincter insufficiency (PASI), which required a large number of repeated operations. The causes of complications were studied, errors were analyzed, indications, timing, accesses, volume and methods of repeated surgery were optimized. The optimization of tactical approaches, methods of surgical and rehabilitation treatment led to the improvement in the results of treatment of PASI up to 85.3%.*

*Conclusions: 1. Indications and the choice of method for repeated correction of pathological conditions in the anorectal zone in children are determined taking into account the degree of PNAS. 2. Analysis of the causes of errors, optimization of diagnostics, tactics of intraoperative surgical correction and postoperative preventive measures contribute to improving the results of treatment of children.*

*3. Optimization of tactical approaches, methods of surgical and rehabilitation treatment led to an improvement in the results of treatment of PNAS up to 85.4%.*

**Key words:** Anorectoplasty; Postoperative Complications; Anorectal Defects; Correction.

**Relevance**

The high frequency of postoperative complications (POC) in the anorectal zone remains an urgent problem of pediatric surgery. Satisfactory results after a single intervention is 50-80% [2,5,10,16,22]. After APM correction, functional disorders of the sphincter apparatus of the rectum are observed in 30-60% of patients, which further leads to fecal incontinence (FI) and chronic constipation (CC) [1,3,4,6,15,20,21]. The software for ARM is caused by diagnostic, tactical and technical errors [7,8,9,19,24,25]. Performing reconstructive operations by surgeons without sufficient experience leads to the development of postoperative complications [11,12,13,14,17,23]. We retrospectively analyzed the causes of the most common recurrent pathological conditions in the anorectal zone in children, as well as tactical approaches, methods of software correction, and considered ways to prevent them.

**The aim of the study** is to improve the results of treatment of children with PO in the anorectal zone based on the study of their causes and to develop preventive measures.

**Material and methods of research.** Under our supervision at the bases (I-GKDB G.Tashkent and MDOB

G.Samarkand) of the hospital of pediatric surgery of TashPMI and SamMI in 2007-2022, there were 197 patients with ARM who underwent various primary corrective operations. Retrospectively, the catamnesis of 78 (39,5%) patients admitted for repeated surgery in the anorectal area for anal and rectal cancer was studied on 37 boys and 41 girls. Age of patients: 3-12 months – 13 (16,6%); 1-3 years – 30 (38,5%); 3-7 years – 23 (29,4%); 8-14 years – 12 (15,4%). The patients underwent 139 reconstructive operations: 42 (53,8%) once, 23 (29,5%) twice, 11 (14,1%) three times and 2 (0,3%) four times.

All patients underwent a comprehensive examination which included anamnesis, clinical examination with rectal examination, laboratory diagnostics, ultrasound with diplography of the vessels of the abdominal cavity and pelvis, myography of the rectal locking apparatus, X-ray examination, MRI and endoscopic examinations.

We have conducted a clinical analysis of the causes of the occurrence of POC during the primary and repeated correction of ARM [anorectal malformation], studied miscalculations and errors, the risk of complications during surgery and developed ways to correct them. The patients were divided into two groups. The first group included 52 (66,7%) patients with PASI [postoperative anal sphincter insufficiency] as a result of the diagnostic, tactical, technical

and combined nature of errors during repeated corrective operations, the second group included 26 (33,3%) patients with PASI due to congenital inferiority of the rectal locking apparatus in combination with regional malformations.

The study was carried out in accordance with the principles of the Helsinki Declaration. The study protocol was approved by the Local Ethics Committee (LEC) of all participating institutions. The informed consent of the children's parents was obtained for the research.

Statistical processing of the study results was carried out using standard methods with the calculation of the absolute number of observations (n) and the percentage ratio (%).

**Results and discussion.** In the first group, retrospective and clinical data of examinations of 58 (74,3%) patients with POC in the anorectal zone after surgical correction of the ARM were studied. The following diagnostic, tactical, technical and combined errors have been identified:

I. Diagnostic: insufficient assessment of the somatic status, defects of neighboring organs and preoperative examination of patients; incorrect X-ray placement of the patient to determine the height of atresia; the extent of stenosis or deviation of the anorectal angle; undiagnosed congenital rectourethral fistulas (RUF); inaccurate identification of the anomaly; incomplete identification of the causes and poor-quality analysis of complications after the initial correction of the ARM.

II. Tactical: incorrect choice of indications, access, radical method of surgery or colostomy when correcting a defect and complications; excessive attempt by perineal access to search for a high atresia blind end of the intestine which in most cases leads to damage to the muscles of the sphincter; insufficient qualification of the surgeon.

III. Technical: incorrect choice of surgical access, violations of the technique of surgery leading to early POC: necrosis of the stump of the reduced intestine as a result of underestimation of the condition of the arcade vessels of the mesentery and, as a consequence, impaired blood supply in the reduced intestine; pelvic peritonitis in the early postoperative period; damage to the muscles of the sphincters as a result of excessive divulsion during intraperitoneal tunneling with a high form of atresia; complete overgrowth of the pelvic floor after repeated

correction; accidental injury of the urethra during repeated mobilization of the colon against the background of a massive adhesive process at the bottom of the pelvis; extra-sphincter reduction of the distal part of the colon; relapses of recto vestibular fistulas (RVF) and ARM due to technical errors of the operation, inadequate choice of method and access; chronic ischemia of the reduced intestine after repeated mobilization and reduction of the short remnants of the colon; intestinal tension or hyperextension of mesenteric vessels and significant intersection of major vessels, leading to impoverishment of blood circulation.

IV. *Combined* – this includes a combination of all types of errors.

In a number of cases, diagnostic errors led to tactical ones regarding the choice of access, and they, in turn, led to technical ones. As a result, the following diseases occurred: stenosis of the anus and rectum; secondary megarectum, which occurs at a late date; prolonged inflammatory processes in the area of the perineal wound in the early postoperative period; discrepancies in the sutures of the wound often occurring against the background of poor preoperative preparation; deformation of the anus with cicatricial degeneration of the external sphincter and defects of the recto-vaginal septum after multiple perineal proctoplasty. The development of the scarring process is caused by tension of the mesentery and insufficient blood supply to the wall of the lowered colon. Defects in the septum of the perineal organs are anatomically manifested in the form of an “artificial cloaca”, and clinically – incontinence of feces and gas. Excessive mucosa of the rectum that occurs after the rectum is reduced. Pararectal fistula that occurs in the early postoperative period against the background of increased pressure by fecal masses, “stones” or during retraction of the reduced intestine, leads to partial divergence of the anastomosis sutures. A pararectal fistula against the background of an inflammatory process or with an enema forms a course in the direction of the perineum and opens far from the anus or the gluteal region. Thus, local manifestations of secondary deformities and pathological conditions of the studied 78 patients were diverse. Our clinical data on the type and number of pathological conditions (nosology) leading to postoperative AAS during surgical correction of ARM in children are shown in Table No.1.

**Table No.1**

**Types and number of pathological conditions leading to POAAS**

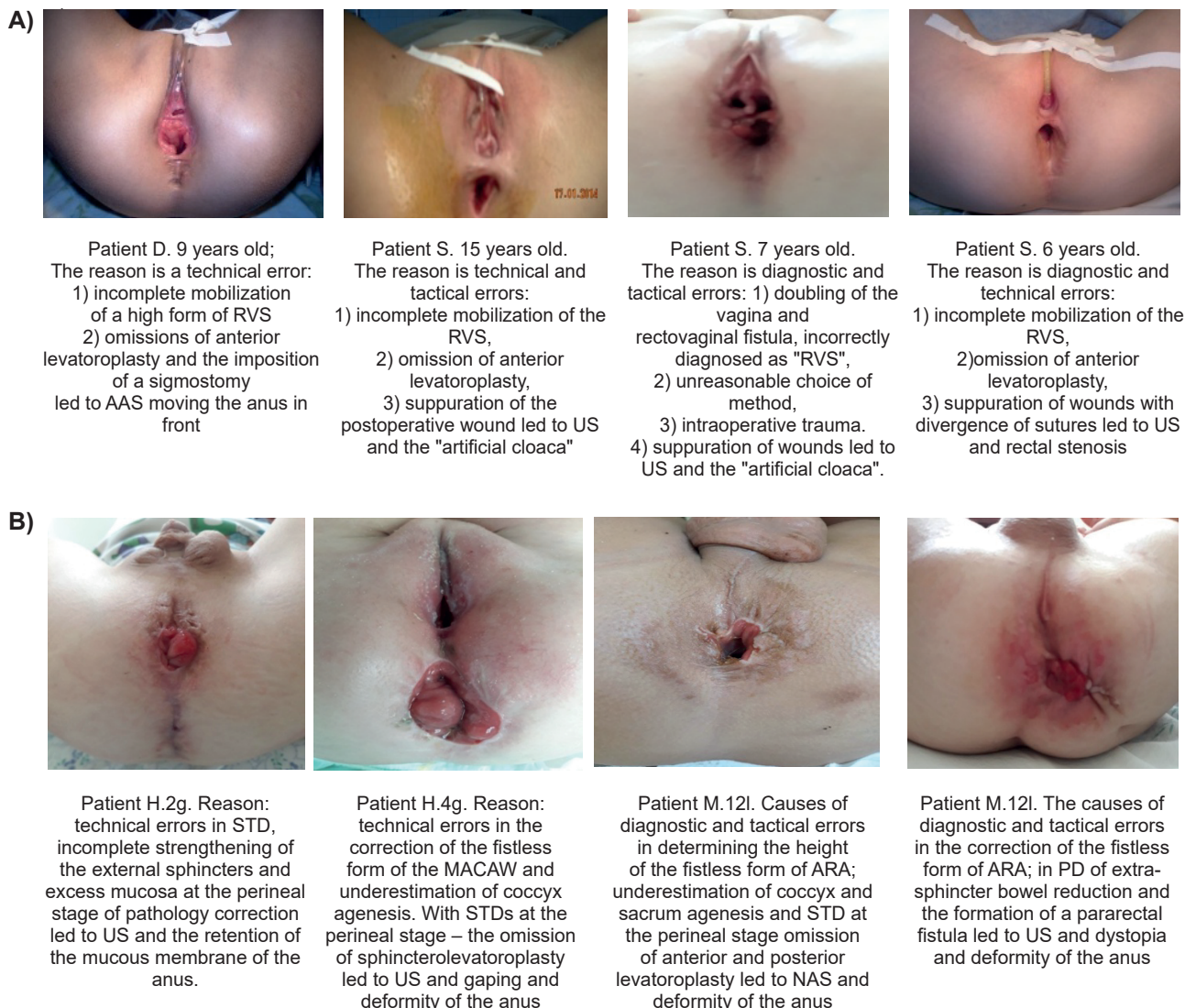№	Types of complications	n	%
1	Recto vaginal septum defect	6	7,6
2	Relapse RVF	10	12,8
3	Scarring of the anus and vagina	7	8,9
4	Untreated stenosis of the anus and rectum	12	15,4
5	Prolonged stenosis of the anus and rectum	5	6,4
6	The acquired «Artificial cloaca»	3	3,8
7	Postoperative anus dystopia	5	6,4
8	Relapse of RVS	7	8,9
9	Extra-sphincter reduction of the colon	3	3,8
10	Pararectal fistula with deformity of the anus	2	2,5
11	Scarring of the anus	7	8,9
12	Retention of the mucosa of the reduced intestine	7	8,9
13	Deformity of the anus with scarring of the external sphincter	4	5,1
	Total	78	100%

Thus, based on all the reasons listed for the unsatisfactory functional results of PONAS, we distinguish into two groups of patients: directly related to diagnostic, tactical and operational-technical errors and not related to them.

The first group of causes of PONAS include intraoperative trauma, unsuccessful repeated operations

and purulent-inflammatory complications due to diagnostic, tactical and technical errors that lead to stenosis or dystopia of the anal canal, deformation of the parotid region, prolapse of the mucosa of the rectum, relapse of the fistula into the urinary or genital system.

We give clinical examples (Fig. 1):



**Fig.1. Pathological conditions leading to PNAS, due to diagnostic and technical errors and complications after the primary correction of rectovestibular fistula-A); and high swish and non-fistulous forms of anorectal atresia -B).**

The second group of causes of PNAS included: violations of the innervation of the pelvic organs due to thickening of the terminal thread of the spinal cord; underdevelopment of the caudal spine (aplasia or agenesis of the sacrum and coccyx) and muscle structures of the sphincter apparatus (aplasia or hypoplasia of the muscle complex); violation of the innervation of the pelvic organs, despite correct primary or repeated anorectoplasty (Fig.2).

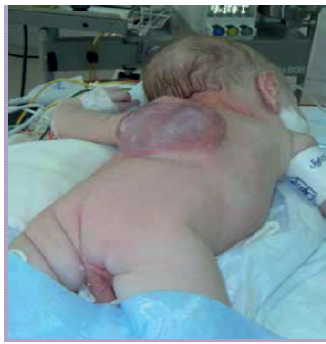Among the congenital pathology leading to PNAS, in 21 (26.9%) of the re-operated patients, we revealed agenesis of the coccygeal and sacrococcygeal vertebrae.

Treatment. Based on a comprehensive examination of 78 patients who underwent repeated operations, tactical

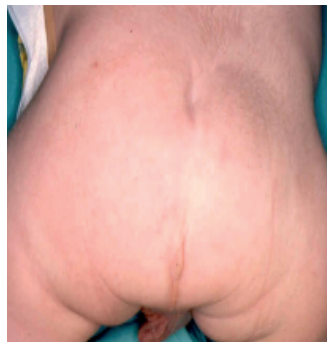approaches to surgical correction were developed, diagnostics and methods of surgical correction, intra- and postoperative measures of prevention of POAAS for each group of patients were optimized. Depending on the severity of POAAS, indications for conservative (rehabilitation) and surgical (re-correction) treatment are optimized.

During the surgical correction of POAAS, we have always sought to ensure the safety of the sphincter apparatus of the rectum, to understand the subtleties of the topographic and anatomical relationships of the perineal organs, to restore the physiological state of the created rectum and anus, to prescribe adequate rehabilitation treatment.

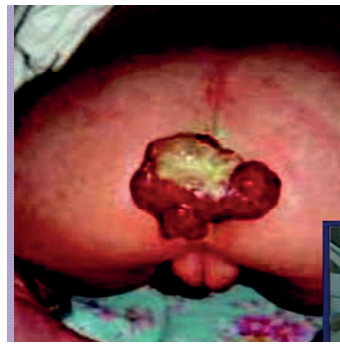



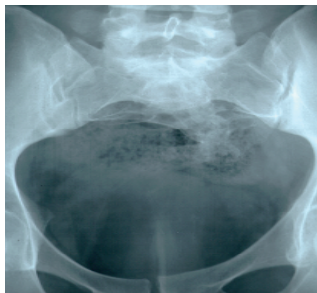Spinal hernia



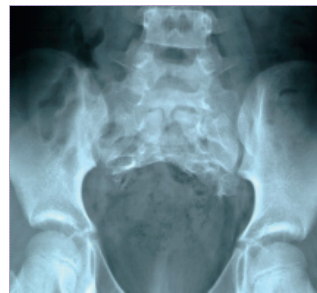Spinal anomaly



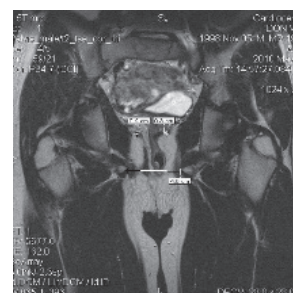
Teratoma of the  
sacrococcygeal region



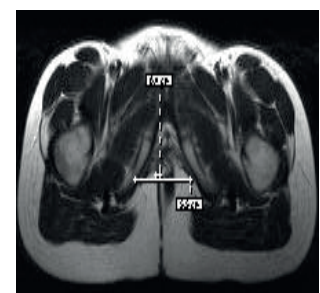
Absence of the right  
half of the sacrum



Sacral agenesis



Hypoplasia  
muscle  
complex



Thickening of the  
terminal thread

**Fig. 2. Congenital pathologies leading to US (uncontrollable) against the background of impaired innervation of the pelvic organs, underdevelopment of the caudal spine and muscle structures of the sphincter apparatus.**

Indications for surgical treatment of the first group of patients were determined by the severity of damage to the muscular structures of the anal sphincter, deformation of the anorectal area and mucosal prolapse. In the absence of pronounced deformity, treatment was started with conservative measures, and if they were ineffective, repeated correction was performed. Augmentation of the anal canal with boughs of increasing diameter from the 14th day after surgical treatment, the use of ointment and rectal candles with lidase. Electrical stimulation of the anal pulp. Rectal gymnastics and training enemas according to the principles of biofeedback for children older than 3-5 years. Development of an individual regime for a patient with an extremely severe form of the defect. In the presence of deformity (stenosis, ectopia, fistulas, defects) and mucosal prolapse, surgical treatment was performed regardless of the degree of damage to the sphincters.

For the prevention of PO during repeated corrective operations, we used the following techniques and intraoperative tactics: if possible, when correcting complications, do without abdominal access; to preserve full blood supply and innervation of the perineum, strive for minimal tissue dissection; accurately remove the rectum through the center of the retaining muscle complex; strive to restore the physiological anorectal angle; preservation of the internal anal sphincter; eliminate tension in the area of the newly formed neoanus. We performed repeated corrective operations with a smaller choice of proctoplasty

in the classical version against the background of gross scarring of perineal tissues (Fig. No.3).

At the same time, we obtained significantly better results of treatment of children (Table No. 2).

Thanks to the optimization of diagnostics, tactics, methods of surgical correction and postoperative measures for the prevention of complications in the first group of patients, it was possible to correct PNAS in 36 cases out of 50, which is 86.2% of cases of good and satisfactory results. The optimal criteria were: optimization of the quality of preoperative diagnosis, preparation of the patient for surgery; timely detection of concomitant anomalies of other organs and systems, professional training of the surgeon, the adequacy of the choice of tactics and techniques for performing corrective surgery, high-quality rehabilitation treatment.

The second group consisted of 21 (26,6%) patients with PNAS due to congenital inferiority of the rectal locking apparatus in combination with regional malformations (aplasia, agenesis of the sacrum and coccyx, hypoplasia of the muscular complex); violation of the innervation of the pelvic organs, NC remained for a long time, despite correct primary anorectoplasty. In this group of patients, in 13 patients with coccyx agenesis, the anococcygeal ligament was additionally restored during repeated corrective surgery. In this category of patients, prolonged electrical stimulation of the anal pulp, rectal gymnastics, training enemas, individual lifestyle, neurological treatment for 3 years led to a satisfactory result in 30% of cases.

Table 2

## The results of surgical treatment of US in the first group of patients

Complication	Conservative treatment and methods of repeated correction	Results, number of patients (n, %)			Total (n, %)
		Good	Satisfied	Unsatisfied	
1. Without significant damage to the external sphincter and slight deformities of the anus (US 1 degree)	Conservative(bougie, anal pulp ESM, physiotherapy, rectal gymnastics and training enemas, neurological treatment)	14 (24,1)	7 (12)	-	21 (36,2)
2. Significant damage to muscle structures + mucosal retention (US 1-2 degrees)	Removal of excess mucosa + levatoroplasty or angioplasty + conservative	9 (15,5)	7 (12)	3 (5,2)	19 (32,8)
3. Significant damage to muscle structures + scarring of the anorectal area (AAS 2-3 degrees)	Anterior or posterior sagittal access is performed by sphincterolevatoroplasty + multiple conservative	8 (13,8)	4 (6,9)	2 (3,4)	14 (24,1)
4. Повреждения всех элементов запирающего аппарата (НАС 3 степени)	STD, SARP, SARP or ARP with reconstruction of the anus with restoration of the puborectal loop, anatomical defects + multiple conservative treatment	-	2 (3,4)	3 (5,2)	5 (8,6)
TOTAL		31 (53,4)	19 (32,8)	8 (13,8)	58 (100)

Thus, tactical approaches to surgical correction of postoperative complications in the anorectal zone in children, leading to US, are not limited to improving surgical techniques, studying the causes of errors, complications, identifying congenital comorbidities, as well as during repeated operations to develop intraoperative and postoperative measures for their prevention, medical and social rehabilitation of patients.

### Conclusions

1. Indications and the choice of method for repeated correction of pathological conditions in the anorectal zone

in children are determined taking into account the degree of PNAS.

2. Analysis of the causes of errors, optimization of diagnostics, tactics of intraoperative surgical correction and postoperative preventive measures contribute to improving the results of treatment of children.

3. Optimization of tactical approaches, methods of surgical and rehabilitation treatment led to an improvement in the results of treatment of PNAS up to 85.4%.

**Conflict of interest:** none.

**Financing:** personal funds.

### References:

- Navruzov SN, Akhmedov MA, Navruzov BS, Shaymardanov EK. Oshibki i oslozhneniya pri vypolnenii operatsiy na anorektal'noy zone [Mistakes and complications on anorectal zone operations]. *Khirurgiya Uzbekistana*. 2014;1:65-9. (In Russian)
- Geraskin AV, Dronov AF, Smirnov AN. Detskaya koloproktologiya [Pediatric coloproctology]. Moskva:«Kontent», 2012; 664 s. (In Russian)
- Shiryaev ND, Kaganov IM. Ocherki rekonstruktivnoy khirurgii naruzhnykh polovoykh organov u detey [Essays on reconstructive surgery of external genitalia in children]. Ch. 2. Syktyvkar, 2012; s. 81. (In Russian)
- Creighton S, Chernausk SD, Romao R, Ransley P, Salle JP. Timing and nature of reconstructive surgery for disorders of sex development – introduction. *J Pediatr Urol*. 2012; 8(6):602-10. doi: 10.1016/j.jpuro.2012.10.001
- Salle JL, Lorenzo AJ, Jesus LE, Leslie B, AlSaid A, Macedo FN, et al. Surgical treatment of high urogenital sinuses using the anterior sagittal transrectal approach: a useful strategy to optimize exposure and outcomes. *J Urol*. 2012;187(3):1024-31. doi: 10.1016/j.juro.2011.10.162
- González R, Ludwikowski B. Management of the high urogenital sinus – risk of overexposure? *J Urol*. 2012;187(3):787-8. doi: 10.1016/j.juro.2011.12.002
- Khamraev AZ, Rakhmonov DB. Repeated Reconstructive Surgeries for Postoperative Complications of Anorectal Malformations in Children. *Indian Journal of Forensic Medicine & Toxicology*. 2020;14(4):7270-8. doi: 10.37506/ijfmt.v14i4.12795
- Khamraev AZh, Rakhmonov DB. Takticheskie podkhody k khirurgicheskoy korrektsii pri posleoperatsionnykh oslozhneniyakh v anorektal'noy zone u detey [Tactical approaches to surgical correction in postoperative complications in the anorectal zone in children]. *Khirurgiya dityachogo viku*. 2019;4(65):55-61. doi: 10.15574/PS.2019.65.55 (In Russian)
- Khamraev AJ, Rakhmonov DB, Raupov FS. Reconstructive operations in postoperative complications of anorectal malformations in children. *Chinese Journal of Industrial Hygiene and Occupational Diseases*. 2021; 10:117-25.
- Bloemendaal AL, Gorissen K, Prapasrivorakul S, Jones OM, Hompes R, Cunningham C, et al. Sacral nerve stimulation for faecal incontinence due to imperforate anus in VATER/VACTERL association. *Int J Colorectal Dis*. 2016;31(3):777-8. doi: 10.1007/s00384-015-2282-y
- Khamraev ADj, Rakhmonov DB. Complications of the IPU of repeated correction of anorectal paroxysms in children. In: *Materials of the annual XXV scientific and practical conference «Experience and prospects for the formation of public health»; 2019 Nov 8; Tadjikistan, Dushanbe; 2019. p. 192.*

12. Zurbuchen U, Groene J, Otto SD, Kreis ME, Maerzheuser S. Sacral neuromodulation for fecal incontinence and constipation in adult patients with anorectal malformation – a feasibility study in patients with or without sacral dysgenesis. *Int J Colorectal Dis.* 2014;29(10):1297-302. doi: 10.1007/s00384-014-1942-7
13. Khamraev ADj, Rakhmonov DB. Repeated reconstructive operations for anorectal malformations in children. In: “Topical issues of colon surgery” Collection of abstracts international online conference. 2021 Mar 12-13; Andijan, 2021. p.102-5.
14. Khamraev ADj, Rakhmonov DB. Postoperative insufficiency of the anal sphincter in children and its surgical correction. In: Materials of the annual XXVII scientific and practical conference with international participation “Modern achievements of medical science and education over the years of independence” dedicated to the 30th anniversary of Independence of the Republic of Tajikistan, 2021. p.52-54.
15. Rakhmonov DB, Azizov MK, Khamraev ADj. Difficulties of repeated reconstructive operations after correction of complicated anorectal malformations in children. In: “Topical issues of pediatric surgery, traumatology, pediatrics and anesthesiology-resuscitation”. Collection of theses of the scientific and practical conference dedicated to the 95th anniversary of the birth of the Doctor of Medical Sciences, MA. Akhmedov. 2021 May 28; Samarkand, 2021. p.90-4.
16. Rakhmonov DB. Postoperative complications of anorectal malformation in children. In: “Actual problems of pediatric surgery” and the First Central Asian Student Scientific and Practical Conference”. Collection of abstracts. 2019 Jun 7; Tashkent, 2019. p. 101-3.
17. Bischoff A, Frischer J, Dickie BH, Peña A. Anorectal malformation without fistula: a defect with unique characteristics. *Pediatr Surg Int.* 2014;30(8):763-6. doi: 10.1007/s00383-014-3527-5
18. Shaul DB, Monforte HL, Levitt MA, Hong AR, Peña A. Surgical management of perineal masses in patients with anorectal malformations. *J Pediatr Surg.* 2005;40(1):188-91. doi: 10.1016/j.jpedsurg.2004.09.027
19. Lagares-Tena L, Millán-Paredes L, Lázaro-García L, Navarro-Luna A, Delgado-Rivilla S, Muñoz-Duyos A. Sacral neuromodulation in patients with congenital faecal incontinence. Special issues and review of the literature. *Tech Coloproctol.* 2018;22(2):89-95. doi: 10.1007/s10151-017-1742-5
20. Lagares-Tena L, Corbella-Sala C, Navarro-Luna A, Muñoz-Duyos A. Sacral neuromodulation in a patient with faecal incontinence and unknown sacral partial agenesis. *Colorectal Dis.* 2017;19(5):502-4. doi: 10.1111/codi.13661
21. Brunner M, Cui Z, Matzel KE. Sacral nerve stimulation for faecal incontinence in patients with sacral malformation. *Int J Colorectal Dis.* 2017;32(6):929-31. doi: 10.1007/s00384-016-2748-6
22. Yang L, Tang ST, Li S, Aubdoollah TH, Cao GQ, Lei HY, Wang XX. Two-stage laparoscopic approaches for high anorectal malformation: transumbilical colostomy and anorectoplasty. *J Pediatr Surg.* 2014;49(11):1631-4. doi: 10.1016/j.jpedsurg.2014.05.014
23. Goossens WJH, de Blaauw I, Wijnen MH, de Gier RPE, Kortmann B, Feitz WFJ. Urological anomalies in anorectal malformations in The Netherlands: effects of screening all patients on long-term outcome. *Pediatric Surgery International.* 2011;27(10):1091-7. doi: 10.1007/s00383-011-2959-4

## РЕЗУЛЬТАТИ ХІРУРГІЧНОЇ КОРЕКЦІЇ ПІСЛЯОПЕРАЦІЙНИХ УСКЛАДНЕНЬ ПРИ АНОРЕКТАЛЬНІЙ МАЛЬФОРМАЦІЇ У ДІТЕЙ

*А. Ж. Хамраєв, Д. Б. Рахмонов, У. А. Хамроєв*

Ташкентський педіатричний медичний інститут,  
Самаркандський державний медичний університет  
(м.Ташкент, Узбекистан)

### Резюме

Актуальною проблемою дитячої хірургії залишається висока частота післяопераційних ускладнень (ПОУ) в аноректальній зоні. Задовільні результати після одноразового втручання становлять 50-80%. Після корекції АПМ у 30-60% пацієнтів спостерігаються функціональні порушення сфінктерного апарату прямої кишки, що в подальшому призводить до нетримання калу (НК) і хронічних запорів (ХЗ). Ретроспективно проаналізовано причини найбільш поширених рецидивуючих патологічних станів аноректальної зони у дітей, а також тактичні прийоми, методи програмної корекції та розглянуто шляхи їх профілактики. Мета – покращення результатів хірургічної корекції післяопераційних ускладнень (ПОУ) в аноректальній зоні у дітей.

Матеріал та методи. Обстежено 78 хворих з ПОУ в аноректальній зоні після первинної та повторної корекції аноректальних мальформацій (АРМ). Проведено 197 реконструктивних операцій. Діагностичний алгоритм складався з клінічного, рентгенологічного, лабораторного обстеження, МРТ та ендоскопічні методи дослідження.

Дослідження виконано відповідно до принципів Гельсінської Декларації. Протокол дослідження схвалено Локальним етичним комітетом (ЛЕК) всіх установ, що беруть участь у дослідженні. На проведення досліджень було отримано поінформовану згоду батьків дітей.

Статистичну обробку результатів дослідження проводили стандартними методами з розрахунком абсолютної кількості спостережень (n) та відсоткового співвідношення (%).

Результати та обговорення. Аналіз віддалених результатів після первинної та повторної корекції АРМ показав, що недостовірною первинною діагностикою, неадекватною передопераційною підготовкою, вибір методу операції призвели до розвитку післяопераційної недостатності анального сфінктера (ПНАС), що вимагало проведення великої кількості повторних операцій. Вивчено причини ускладнень, проаналізовано помилки, оптимізовано показання, терміни, доступи, обсяг та методи повторної операції. Оптимізація тактичних підходів, методів хірургічного та реабілітаційного лікування сприяли покращенню результатів лікування ПНАС до 85,3%.

Висновки: 1. Показання та вибір методу повторної корекції патологічних станів аноректальної зони у дітей визначаються з урахуванням ступеня ПНАС. 2. Аналіз причин помилок, оптимізація діагностики, тактики інтраопераційної хірургічної корекції та післяопераційних профілактичних заходів сприяють покращенню результатів лікування дітей. 3. Оптимізація тактичних підходів, методів хірургічного та реабілітаційного лікування призвела до покращення результатів лікування ПНАС до 85,4%.

**Ключові слова:** аноректопластика; післяопераційні ускладнення; аноректальні вади; корекція.

**Contact Information:**

**Abdurashid Khamraev** – Doctor of Medical Sciences, Professor of the Department of Hospital Pediatric Surgery of the Tashkent Pediatric Medical Institute (Tashkent, Republic of Uzbekistan)

**e-mail:** abdurashid-56@rambler.ru

**ORCID:** <https://orcid.org/0000-0002-7651-8901>

**Dilshod Rakhmonov** – PhD of the Deputy, Chief physician of the regional multidisciplinary children's hospital of Samarkand (Samarkand, Republic of Uzbekistan)

**e-mail:** dilshod.rahmonov81@mail.ru

**ORCID:** <https://orcid.org/0009-0004-8838-2855>

**Ulugbek Khamroev** – PhD of the Department of Hospital neonotals surgery of the Republic Perinatals Center Tashkent Pediatric Medical Institute (Tashkent, Republic of Uzbekistan)

**e-mail:** ulugbek307@rambler.ru

**ORCID:** <https://orcid.org/0000-0001-6269-5862>

**Контактна інформація:**

**Хамраєв Абдурашид Джуракулович** – д.мед.н., професор кафедри госпітальної дитячої хірургії Ташкентського педіатричного медичного інституту (м. Ташкент, Республіка Узбекистан)

**e-mail:** abdurashid-56@rambler.ru

**ORCID:** <https://orcid.org/0000-0002-7651-8901>

**Рахмонов Дільшод Бурхонович** – к.мед.н., заступник, головний лікар обласної багатопрофільної дитячої лікарні м. Самарканд (м. Самарканд, Республіка Узбекистан)

**e-mail:** dilshod.rahmonov81@mail.ru

**ORCID:** <https://orcid.org/0009-0004-8838-2855>

**Хамроєв Улугбек Абдурашидович** – к.мед.н., завідувач кафедри госпітальної хірургії новонароджених республіканського перинатального центру Ташкентського педіатричного медичного інституту (м. Ташкент, Республіка Узбекистан)

**e-mail:** ulugbek307@rambler.ru

**ORCID:** <https://orcid.org/0000-0001-6269-5862>



Received for editorial office on 12/05/2023

Signed for printing on 15/08/2023