

ВИПАДКИ З ПРАКТИКИ / CASES FROM PRACTICE

UDC: 616.831-009.24-056.7-07-08-053.66
DOI: 10.24061/2413-4260.XIII.1.47.2023.7

GENETIC EPILEPTIC AND
DEVELOPMENTAL ENCEPHALOPATHIES
OF THE EARLY AGE: FROM SYMPTOMS
GENETIC TESTING TO DIAGNOSIS

*L. Kyrylova, O. Yuzva, O. Miroshnykov,
N. Bondarenko, O. Beregela*

SI «O.M. Lukyanova Institute of Pediatrics, Obstetrics and Gynecology NAMS of Ukraine», Kyiv, Ukraine. President of the All-Ukrainian Public Organization "Association of Pediatric Neurologist of Ukraine" (Kyiv, Ukraine)

Summary

Introduction. *The problem of early diagnostics of orphan diseases is relevant for most countries of the world. The challenge for healthcare is to prevent new cases of orphan diseases by providing medical genetic testing and counseling at the stage of family planning. Department of psychoneurology of the State Institution "Institute of Pediatrics, Obstetrics and Gynecology named after Academician O.M. Lukyanova National Academy of Medical Sciences of Ukraine" has been dealing with the problem of orphan diseases since 2012 and has significant experience in their diagnosis and treatment in children.*

The aim of paper: *to develop an algorithm for the genetic diagnosis of epileptic and developmental encephalopathies in children with developmental delay and dimorphic features based on modern data on the application and interpretation of genetic methods. A case which demonstrate the complexity of interpreting the results and algorithms for early diagnosis of patients and the importance of medical and genetic counseling is presented*

Material and methods: *clinical and neurological examination, sleep video-EEG monitoring during night sleep, brain magnetic resonance imaging (3.0T), whole-exome sequencing (WES).*

Results. *The article presents the algorithm of genetic diagnosis of orphan diseases in children with developmental and epileptic encephalopathies, developmental delay, and dimorphic features. A clinical case of a boy with general developmental delay and atonic epileptic seizures is presented. Sleep EEG-monitoring showed epileptiform activity in the stage of slow-wave sleep localized in the central-parietal and left temporal areas in the form of benign childhood epileptiform patterns.*

Whole-exome sequencing detected a variant of uncertain significance (VUS) c.5887C>T(p.Arg1963Cys) of SON gene in a heterozygous state, which leads to the replacement of arginine to cysteine. Mutations in the SON gene in the heterozygous state have been described in patients with Zhu-Tokita-Takenouchi-Kim syndrome (OMIM: 617140).

Conclusions: *It is important for pediatricians and neurologists to be aware of orphan diseases in children with developmental and epileptic encephalopathies and developmental delay. Genetic tests are wide available but they require competent interpretation by clinicians. After obtaining the results, it is important to compare the obtained result with the phenotype of patient. In case the phenotype of patient match and the results of genetic test, (detected VUS) this mutation could be etiological factor of the disease. In our case, the clinical signs coincided with those described in 2015 by the authors of the first description of Zhu-Tokita-Takenouchi-Kim syndrome, and therefore genetic testing helped to verify the final diagnosis. Therefore genetic counseling is extremely important for detection of etiology and prognosis of early developmental and epileptic encephalopathies/*

Keywords: *Zhu-Tokita-Takenouchi-Kim syndrome; autism spectrum disorder; epilepsy; whole-exome sequencing; medical and genetic counseling; variant of uncertain significance.*

Introduction

Protection of mother and child health is one of the global problems that humanity must deal with for the sake of its own survival on the planet. According to the richest man in the world, Elon Musk, the decline in the birth rate and perinatal losses is one of the 3 global threats to the existence of humanity. In preserving the health of the population, an important role is assigned to medical and genetic counseling, which should be carried out at the stage of pregnancy planning in all cases when the family already has a child with a neurodevelopmental disorder or developmental delay. However, one of the conditions for its implementation is a clearly established nosological diagnosis of a child with a neurodevelopmental disorder or other neurological disorder.

Development delay is a common complaint of most parents who consult with a pediatric neurologist. Delays may occur in the areas of motor function, speech and language, cognitive, play, and social skills.

The etiology of developmental delay and neurodevelopment disorders in children is heterogeneous, namely, genetic, infectious and metabolic. In some cases, developmental delay is the only clinical sign, while in others it belongs to the spectrum of symptoms of a certain syndrome. It is important to differentiate between delay and regression, which often occurs in epileptic or epileptiform encephalopathies (EE).

Epileptic encephalopathies (EE) Epileptic encephalopathies refer to a group of disorders in which the unremitting epileptic activity contributes to severe cognitive and behavioral impairments above and beyond what might be expected from the

underlying pathology alone, and these can worsen over time leading to progressive cerebral dysfunction. The presence of continuous epileptiform activity of the cerebral cortex exceeds the clinical manifestations expected only from the main brain pathology (for example, cortical malformation), which may worsen over time and lead to progressive cerebral dysfunction [1]. In most cases, EE can cause not only the regression of social and communication skills, but also lead to restricted and repetitive behavior and other symptoms of autism spectrum disorder (ASD) [2,3].

Cohort studies in the USA showed that the incidence rate of EE and other forms of epilepsy is highest among children under 5 years of age (> 60/100,000). Some population studies have shown a much higher incidence in children under 5 years of age than in older children (82.1-118 vs. 46/100,000 children). Recent prospective population-based studies have found an incidence of 195/100,000 live births, which is higher than previous studies in developed countries [4-6].

The course of EE can be static or progressive. Over time, with EE, both individual cognitive or language functions of the child, as well as the entire development as a whole, can regress, leading to the development of ASD. In children, both epileptic seizures and interictal epileptiform activity of the brain by itself can be noted, which is manifested by changes in the electroencephalogram in EE without convulsive attacks, but can directly worsen the child's cognitive functions and behavior. These disorders can vary greatly in severity and occur at any age. Timely treatment of seizures and pathological changes displayed on the EEG can not only reduce the frequency of seizures, but also improve the child's cognitive, communicative, language and behavioral development [7-9].

The etiological factor of EE in children is heterogeneous and includes several causes, such as structural, infectious, metabolic and genetic. According to the literature, there are monogenic forms of epilepsy caused by a mutation in one gene and polygenic forms as a result of mutations in several genes. Genetic causes of epilepsy fall into two categories:

- 1) genes associated with primary epilepsy;
- 2) genes associated with neurological disorders in which epilepsy may be a symptom.

It is especially difficult to establish a correct diagnosis when developmental delay is one of the signs of an orphan disease. Due to the fact that they are rare in the population, patients visit more than one specialist before the correct diagnosis is made, while in 40% of cases a rare disease is misdiagnosed at least once. It was found that it takes about 4.8 years on average from the first symptoms of an orphan disease to the establishment of an accurate diagnosis [10]. Although the term "orphan diseases" was first introduced into the medical nomenclature in 1983, today about 8,000 nosologies are known [11]. About 80% of rare diseases are genetically determined and most of them have a progressive course and significantly worsen the quality of life of the child [12]. Almost 75% of orphan diseases appear in early childhood and in 30% of cases children die

before the age of 5 [13,14].

The introduction into clinical practice of such genetic research as next generation sequencing (NGS - next generation sequencing), which allows for genome analysis, made a certain breakthrough in the diagnosis of orphan genetic, including epileptic encephalopathy. In recent years, a number of monogenic syndromes manifested by epileptic and developmental encephalopathy have been discovered. In particular, genes whose mutations are associated with the development of epileptic and developmental encephalopathy include ARX, CDKL5, SLC25A22, STXBP1 and SPTAN1 and many others [15,16].

The difficulty of interpreting the results of genetic research is illustrated by the clinical case of the diagnosis of Zhu-Tokita-Takenouchi-Kim syndrome in a boy with cognitive and speech development delayed and epileptic seizures, which were not diagnosed in time.

In this article, we present a clinical case of a de novo mutation of the SON gene in a child who was treated for 3 years with a diagnosis of epileptic encephalopathy and undifferentiated mitochondrial dysfunction with myopathic syndrome. This case of Zhu-Tokita-Takenouchi-Kim syndrome is described for the first time in Ukraine and demonstrate the complexity of the process of diagnosing of orphan diseases.

Clinical case

The 3-year-old boy was admitted to psychoneurology department with complaints from his mother for the child's motor, psychology and language development delay, atonic epileptic seizures (falls).

From the anamnesis it is known that the child was born from the second pregnancy, which was uneventful (the daughter from the first pregnancy was healthy). The delivery was timely, by caesarean section. Birth weight - 3350 g, body length - 51 cm, Apgar score - 9 points. For age of year, he was observed for problem that child could not eat liquid food (powdering, pouring through the nose). Motor, psychology and language development was delayed. He was operated due to bilateral cryptorchidism at the age of 9 months. He held his head from 11 months, sitting independently from 1 year 2 months, walked independently from 1 year 7 months. Time of time received courses of restorative treatment. He was observed in the medical and genetic center of Kharkiv, with a diagnosis of undifferentiated mitochondrial myopath. In 2019, an MRI of the brain was performed – which showed gray matter heterotopia. In January 2020, ENMG was performed^ EMG signs of the primary muscular process, involvement of spinal cord motoneurons, current denervation changes in the muscles were not detected.

Status objectives - manifestations of body weight deficiency (weight 12 kg). The skin is clean, the mucous membrane of the pharynx is pink. Signs of dysmorphism in the form of macrocephalic syndrome, deep-set eyeballs, drooping of the upper eyelid, strabismus, open nostrils, raised nose (Fig. 1). Heart tones are sonorous and rhythmic. Above the lungs was vesicular breathing. Abdomen is soft, painless. Physiological functions are not disturbed.

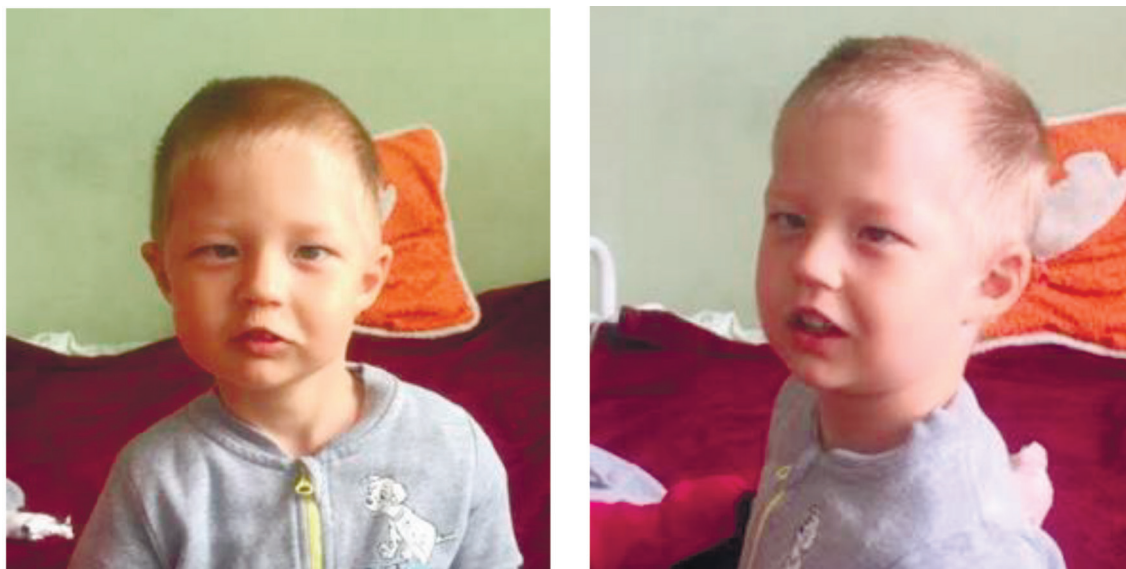

Figure 1. A child with Zhu-Tokita-Takenouchi-Kim syndrome (parental consent was obtained for the publication of the photo).

Neurological status - the child is in conscious, responds calmly to the examination, perform individual instructions. He could repeats a few words, but spontaneous speech is absent. The head is macrocephalic, the circumference of the head is 48.5 cm. Convergent braid is more on the right. Muscle tone is reduced D=S, mainly in the lower limbs. Tendon reflexes from the upper limbs are evoked by D=S, alive. Knee reflexes are not evoked, D=S. Independent walking. Babinski's symptom is negative D=S. There were no sensitivity disorders. There were no meningeal symptoms.

During EEG monitoring, changes in brain biorhythms were detected in the form of a diffuse periodic slowing of the main activity. Epileptiform activity is registered during sleep in the central-parietal and left temporal regions. Sharp-slow wave complexes with an amplitude of up to 150 μ V and a frequency of 3-4 Hz, in the form of benign epileptiform patterns of childhood (DEPD).

During the MRI examination of the brain was significant enlarged of subependymal to the lateral ventricles, bilaterally more to the left, single isointense foci measuring 0.5x0.4 cm. Conclusion: MRI signs of heterotopia of the gray matter of the brain.

Tandem mass spectrometry of amino acids and acylcarnitines was performed - according to the results of the analysis, no violation of the content of the investigated metabolites in the blood was detected.

Next-generation sequencing (NGS) research using whole exome sequencing found a SON gene mutation c.5887C>T(p.Arg1963Cys), which is associated with the development of the autosomal dominant Zhu-Tokita-Takenouchi-Kim syndrome. According to the ClinVar database of genetic variants, this variant is characterized as a variant of uncertain significance (VUS – variant of uncertain significance).

After obtaining such a result, the clinician faces an extremely important task, namely, to compare the obtained result with the clinical signs of the described syndrome. Only if the clinical manifestations and VUS match, we can say that this mutation is the etiological factor of the disease. In our case, the clinical signs in the boy coincided with those described

by the pioneers of the Zhu-Tokita-Takenouchi-Kim syndrome; thus, the conducted study helped establish the final diagnosis: Genetically determined epileptic encephalopathy with periventricular heterotopia, mitochondrial dysfunction, myopathic syndrome, congenital cryptorchidism, and psycho-speech delay is caused by a gene mutation SON, or Zhu-Tokita-Takenouchi-Kim syndrome.

Discussion

The discovery of mutations in genes that lead to the development of EE and ASD contributed to the expansion of our knowledge about the causes of the development of these disorders. In addition, with the advent of targeted ("target" - "goal") therapy, new treatment methods are increasingly used purposefully for the treatment of some genetically determined forms of EE and neurodevelopmental disorders [14-17].

In the department of psychoneurology for children with perinatal pathology and orphan diseases of the State Institution "IPAG named after acad. O.M. Lukyanova National Academy Medical Sciences of Ukraine", we have accumulated some experience in examining children with EE, developmental delay ASD, which were based on EE and were classified as organic or "rare" diseases. Taking into account the data of the world literature and the results of our own research, we developed an algorithm for genetic diagnosis in patients with EE and ASD.

Genetic methods allow in many cases to timely and accurately diagnose the etiology of EE and ASD. Practically, it can help to optimize the diagnostic search time for the patient and his family, give a prognosis regarding the further course of the disease, and also adjust treatment tactics.

However, before genetic testing, it is important to perform the necessary laboratory tests, such as biochemical and metabolic tests, EEG monitoring during night sleep, and neuroimaging (brain MRI) [18]. It is imperative to consult with parents, they should be consulted to discuss the indications, limitations of testing, and the possible consequences of receiving a positive, negative, or ambiguous result (if variants of uncertain value are detected) [19,20].

Indications for genetic testing in EE with manifestations of ASD are:

- presence of a negative prognosis for the course of the disease based on clinical data and EEG results;
- resistance to treatment epileptic seizures without an identified cause;
- suspected congenital metabolic disorder.
- suspicion of a neurodegenerative disease;
- suspicion of a neuro-cutaneous disease (phakomatosis);
- the child has signs of a genetic syndrome, such as delayed motoric development, intellectual disability, multiple congenital anomalies or dysmorphic facial features;
- accompanying neurological disorders (tone disorders, movement disorders, hearing or vision disorders);
- abnormal dimensions of the head circumference (micro- or macrocephaly);
- presence of cases of epilepsy in the family (at least two family members of the first degree of consanguinity)
- early deaths of children in the family or other close family members, the cause of which has not been established.

Current methods of genetic diagnostics include:

- 1) studying of karyotype - used to diagnose chromosomal abnormalities (for example, in multiple developmental defects, dysmorphic facial features);
- 2) chromosomal microarray analysis (CMA), also known as the method of comparative genomic hybridization (array comparative genomic hybridization (CGH)), is used in the presence of dysmorphic facial features, concomitant somatic pathology, developmental defects;
- 3) next generation sequencing (NGS), which may include the study of individual genes (for example, TSC1) or a panel of genes;
- 4) whole exome (WES) and genomic sequencing

(WHS).

A studying of karyotype can be useful in the case of EE in combination with dysmorphic features of the face and signs of lesions of other organs or systems, visual or hearing disorders. Karyotyping can help detect rearrangements such as translocations, aneuploidies, or ring chromosomes.

The method of chromosomal microarray analysis (CMA) is recommended for children with EE and intellectual disability in combination with dysmorphic features of the face, congenital anomalies. CMA allows detection of gene copy number variants, but balanced rearrangements, point mutations, and small exon deletions and duplications may be missed. The diagnostic value of the CMA method for EE is from 5 to 16%.

Monogenic testing should be performed in case of clinical manifestations of EE, which makes it possible to clearly suspect a specific monogenic syndrome, for example, Dravet syndrome, tuberous sclerosis, or GLUT-1 transporter deficiency.

If the clinical picture is undifferentiated and a specific monogenic form of EE cannot be suspected, gene panel studies or whole exome sequencing should be preferred. Gene panels offered by commercial laboratories allow screening of hundreds of genes simultaneously by the method of next generation sequencing (NGS). The effectiveness of gene panel research in EE ranges from 15 to 25%.

However, it should be remembered that the number of genes contained in the panel is usually only about 1% of the entire genome. Therefore, children under 6 years old with a diagnosis of epileptic encephalopathy and ASD are recommended to include genetic testing by the NGS method through whole exome sequencing (WES) in a comprehensive examination (EEG, EEG monitoring during night sleep, MRI of the brain). The effectiveness of WES (examination of the child and parents) in EE ranges from 20 to 40% (Fig. 2).

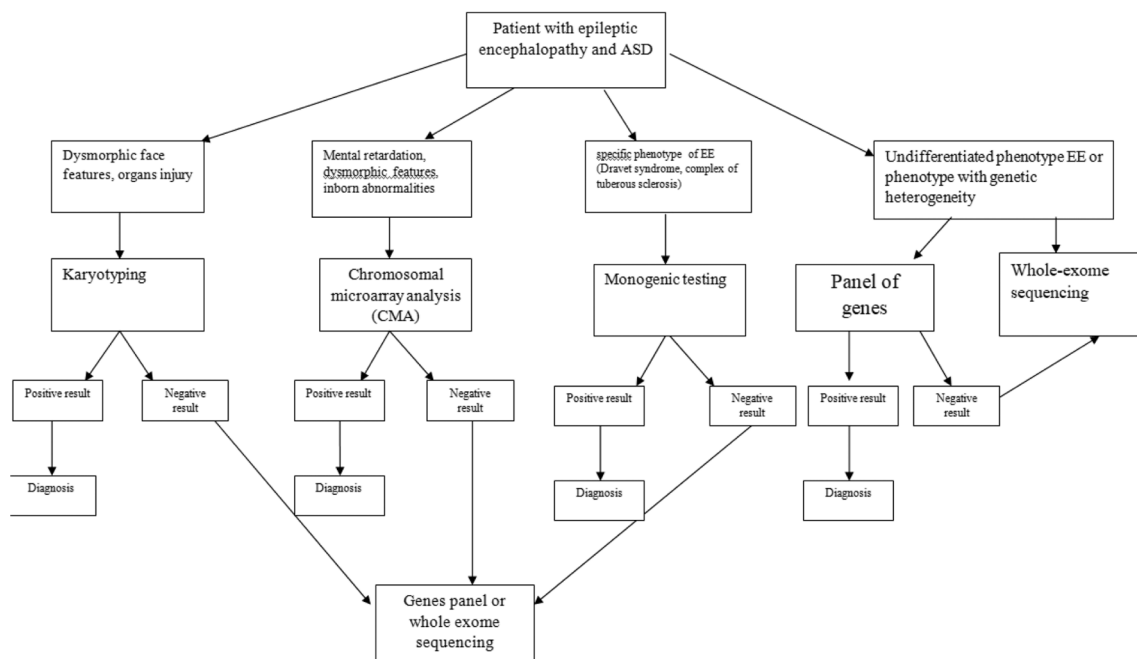


Figure 2. Algorithm for diagnosis of epileptic EE and ASD.

When examining a child with EE and ASD in combination with mental retardation, congenital malformations, dysmorphic features and lesions of internal organs, it is recommended to start genetic examination with karyotyping or chromosomal micrometric analysis. With a specific epileptic encephalopathy phenotype (for example, suspicion of tuberous sclerosis or Dravet syndrome), monogene testing is possible. For an undifferentiated phenotype of epileptic encephalopathy, a gene panel or WES should be performed.

The whole exome sequencing (WES) method is the most accessible and cost-effective today. The method makes it possible to detect inherited or newly formed (de novo) variants of the nucleotide sequence (single nucleotide substitutions, small insertions and deletions - up to 10 bp), which can be the cause of the development of EE with manifestations of ASD. The method is not intended to assess the level of methylation or detect mutations in the mosaic state. In some cases, bioinformatics data analysis allows us to suspect the presence of structural rearrangements (micro deletions and micro duplications). However, this approach is not a recommended method for the analysis of variations in the number of copies of genes (CNV), and the detected rearrangements are subject to mandatory confirmation by a reference method (CMA). Minor structural disorders, uniparental disomy and mosaic variants of the number of gene copies are not detected by sequencing; for this, a validated method of CMA should be used. The absence of structural variants during sequencing does not exclude their presence in the patient. Examination of the parents of the proband or other relatives may be necessary to establish the origin (inherited / de novo) of the detected variant and clarify its pathogenicity.

The obtained NGS results are evaluated according to the criteria and guidelines for interpretation established by the American College of Medical Genetics and Genomics (ACMG). Test results should always be interpreted in the context of family history, medical history, and current information about the disease. The obtained results are discussed by the patient with the neurologist who referred the patient for examination and the geneticist [19].

The results of genetic testing using the NGS method make it possible to obtain various variants of mutations in genes associated with the development of orphan diseases. According to the classification of the American College of Medical Genetics and Genomics, these variants can be interpreted as follows [20, 21]:

- 1) pathogenic;
- 2) probably pathogenic (likely pathogenic);
- 3) variant of uncertain significance (VUS);
- 4) likely benign;
- 5) benign.

After receiving the results of genetic research, it is necessary to comprehensively approach the conduct of medical and genetic testing at the stage of family planning. In particular, after receiving a pathogenic or probably pathogenic mutation variant in the research results, it is necessary to conduct a study of the parents of the sick child to establish the reliability of the obtained pathogenic mutation. In most cases, orphan diseases are characterized by de

novo mutations with an autosomal dominant type of inheritance, and therefore parents should not have these mutations. However, situations often arise when parents are carriers of genetic mutations in an autosomal recessive state and are manifested only in subsequent generations. Therefore, medical and genetic counseling is extremely important to prevent the spread of orphan diseases in the population.

Zhu-Tokita-Takenouchi-Kim (ZTTK) syndrome (OMIM 617140) belongs to a group of developmental disorders with heterogeneous clinical manifestations, including intellectual deficit. ZTTK is inherited in an autosomal dominant pattern and is caused by a mutation of the SON gene [22,23]. The SON gene belongs to DNA-coding proteins and is located on chromosome 21q22.11. It consists of 12 exons. Exon 3 is the largest, accounting for 82% of the entire coding region with the majority of SON variants found in patients with ZTTK located in this region [24,25]. All described cases of ZTTK were the result of de novo mutations of the SON gene.

For the first time, a case of ZTTK syndrome was described by Zhu et al. in 2015 in a 5-year-old girl with developmental delay, epilepsy, mild facial dysmorphism, megalencephaly, cerebral white matter hypoplasia, intestinal atresia, and ventricular septal defect. A new heterozygous microdeletion variant c.5753_5756del was discovered, which leads to premature termination of the codon in the SON gene [26]. In 2016, Takenouchi et al. reported the same frameshift variant in the same locus of the SON gene in a boy with similar clinical manifestations [27]. Later, Takita et al. described 7 children with de novo pathogenic variants in the SON gene and found that these variants were associated with a severe multisystem disorder. In 2016, 20 children with de novo pathogenic variants in the SON gene with common phenotypic manifestations and neurodevelopmental disorders were already described [24,28]. Kim et al. also found that SON haploinsufficiency leads to defective RNA splicing of several genes critical for neuron development [29]. According to data from the portal orpha.net, as of 2020, 33 cases of ZTTK syndrome have been registered, and its frequency is estimated at <1:1,000,000 [30].

Clinical manifestations of ZTTK are extremely polymorphic and are currently still being actively investigated. Clinical manifestations can be classified by organs and systems [25-31]:

- 1) Ophthalmological symptoms: optic nerve atrophy, cortical visual disturbances, strabismus, nystagmus.
- 2) Dysmorphic facial features: deep-set eyes, slanted downward palpebral fissure, horizontal eyebrows (Mongoloid type), facial asymmetry, low-set ears, indentation of the middle of the face, protruding forehead, wide bridge of the nose, flattened shortened filter.

3) Systemic symptoms: congenital malformations (quite often of cardiovascular or genitourinary symptoms), joint hypermobility and hypotension. During the neonatal period, persistent feeding difficulties that lead to a lack of physical development.

4) Neurological manifestations: general developmental delay against the background of muscle hypotonia, which becomes pronounced with

age, impaired development of fine motor skills; delayed expressive and receptive language development or autism spectrum disorder. Macrocephalic syndrome. Epileptic syndrome especially at the age of 1 to 6 years.

5) MRI of the brain: abnormalities in the development of gyri, including polymicrogyria, periventricular nodular heterotopias, were noted in some children.

It is known that the SON gene plays a key role in the maturation and differentiation of undifferentiated stem cells. In experiments on mice, it was proved that this gene plays one of the key roles in the migration of neurons of the neural tube in the process of ontogenesis, and its mutations may lead to congenital malformations of the central nervous system (for example, heterotopias or cortical dysplasia) [22]. Haploinsufficiency of the SON gene causes reduced mRNA expression and impaired RNA splicing of many genes that are necessary for nerve cell migration, metabolic processes, kidney and brain development [33-35]. Thus, it was proved that SON, as a regulator of RNA splicing, plays a significant role in neurodevelopment.

In addition to the maturation of the nervous system, the SON gene has an impact on metabolic processes. SON gene mutations may affect mitochondrial metabolism and function in newborns with ZTTK syndrome. Metabolic screening confirmed

mitochondrial dysfunction and O-glycosylation defects in individuals with ZTTK syndrome. A decrease in the level of immunoglobulins A and G is also characteristic of patients with ZTTK syndrome [36].

Conclusions: When faced with a rare disease in a child, a clinician may make a clinical diagnosis of a known syndrome or disease. However, many orphan diseases in children present under the clinical "masks" of diseases such as cerebral palsy, hydrocephalus, epilepsy, mental retardation, and autism spectrum disorders. It is important for a pediatrician to be alert to the detection of orphan diseases and to approach their diagnosis comprehensively, with due regard for clinical signs, etiology, and pathogenesis.

An orphan disease can only be diagnosed if an active search is made to clarify the diagnosis. Genetic tests are available and open up new diagnostic possibilities, but require competent interpretation by a clinical specialist.

Timely treatment is the key to a positive prognosis, and medical genetic counseling at the family planning stage reduces the risk of spreading orphan diseases in the population.

The authors declare no conflict of interest.

Sources of funding: self-financing

Reference

- Morrison-Levy N, Borlot F, Jain P, Whitney R. Early-Onset Developmental and Epileptic Encephalopathies of Infancy: An Overview of the Genetic Basis and Clinical Features. *Pediatr Neurol.* 2021;116:85-94. doi: 10.1016/j.pediatrneurol.2020.12.00
- McTague A, Howell KB, Cross JH, Kurian MA, Scheffer IE. The genetic landscape of the epileptic encephalopathies of infancy and childhood. *Lancet Neurol.* 2016;15(3):304-16. doi: 10.1016/S1474-4422(15)00250-1
- Srivastava S, Sahin M. Autism spectrum disorder and epileptic encephalopathy: common causes, many questions. *J Neurodev Disord* [Internet]. 2017[cited 2022 Nov 11];9:23. Available from: <https://jneurodevdisorders.biomedcentral.com/articles/10.1186/s11689-017-9202-0> doi: 10.1186/s11689-017-9202-0
- Aaberg KM, Gunnes N, Bakken IJ, Lund Søråas C, Berntsen A, Magnus P, et al. Incidence and Prevalence of Childhood Epilepsy: A Nationwide Cohort Study. *Pediatrics* [Internet]. 2017[cited 2022 Nov 11];139(5):e20163908. Available from: <https://publications.aap.org/pediatrics/article-abstract/139/5/e20163908/38809/Incidence-and-Prevalence-of-Childhood-Epilepsy-A?redirectedFrom=fulltext> doi: 10.1542/peds.2016-3908
- Berg AT, Zelko FA, Levy SR, Testa FM. Age at onset of epilepsy, pharmacoresistance, and cognitive outcomes: a prospective cohort study. *Neurology.* 2012;79(13):1384-91. doi: 10.1212/WNL.0b013e31826c1b55
- El Achkar CM, Olson HE, Poduri A, Pearl PL. The genetics of the epilepsies. *Curr Neurol Neurosci Rep.* 2015;15(7):39. doi: 10.1007/s11910-015-0559-8
- American Psychiatric Association. Diagnostic and statistical manual of mental disorders (DSM-5-TR) [Internet]. Washington: American Psychiatric Association; 2022[cited 2022 Nov 11]. Available from: <https://psychiatry.org/psychiatrists/practice/dsm>
- Karimi P, Kamali E, Mousavi SM, Karahmadi M. Environmental factors influencing the risk of autism. *J Res Med Sci* [Internet]. 2017[cited 2022 Nov 11];22:27. Available from: <https://www.ncbi.nlm.nih.gov/pmc/articles/PMC5377970/pdf/JRMS-22-27.pdf> doi: 10.4103/1735-1995.200272
- de la Torre-Ubieta L, Won H, Stein JL, Geschwind DH. Advancing the understanding of autism disease mechanisms through genetics. *Nat Med.* 2016;22(4):345-61. doi: 10.1038/nm.4071
- Engel PA, Bagal S, Broback M, Boice N. Physician and patient perceptions regarding physician training in rare diseases: the need for stronger educational initiatives for physicians. *J Rare Disord* [Internet]. 2013[cited 2022 Nov 11];1(2):1-15. Available from: <https://www.engagehealth.com/current-issues/insights-publications/physician-and-patient-perceptions-regarding-physician-training-in-rare-diseases-the-need-for-stronger-educational-initiatives-for-physicians/>
- Bavisetty S, et al. Emergence of pediatric rare diseases. *Rare Dis* [Internet]. 2013[cited 2022 Nov 11];1:e23579. Available from: <https://www.ncbi.nlm.nih.gov/pmc/articles/PMC3932940/pdf/rdis-1-e23579.pdf> doi: 10.4161/rdis.23579
- Rare Diseases UK. Key Statistics from the RDUK Report 'Experiences of Rare Diseases: An Insight from Patients and Families'. Available from: <http://raredisease.org.uk/index.htm>
- Limb L, Nutt S, Sen A. Experiences of Rare Diseases: An Insight from Patients and Families [Internet]. *Rare Diseases UK; 2010*[cited 2022 Nov 11]. 37 p. Available from: <https://www.raredisease.org.uk/media/1594/rduk-family-report.pdf>
- The Voice of 12,000 Patients. Experiences and Expectations of Rare Disease Patients on Diagnosis and Care in Europe [Internet]. *EURORDIS - Rare Diseases Eu; 2009*[cited 2022 Nov 11]. 324 p. Available from: https://www.eurordis.org/IMG/pdf/voice_12000_patients/EURORDISCARE_FULLBOOKr.pdf
- Weiss LA, Escayg A, Kearney JA, Trudeau M, MacDonald BT, Mori M, et al. Sodium channels SCN1A, SCN2A and SCN3A in familial autism. *Mol Psychiatry.* 2003;8(2):186-94. doi: 10.1038/sj.mp.4001241
- Sanders SJ, Murtha MT, Gupta AR, Murdoch JD, Raubeson MJ, Willsey AJ, et al. De novo mutations revealed by whole-exome sequencing are strongly associated with autism. *Nature.* 2012;485:237-41. doi: 10.1038/nature10945

17. Pisano T, Numis AL, Heavin SB, Weckhuysen S, Angriman P, Suls A, et al. Early and effective treatment of KCNQ2 encephalopathy. *Epilepsia*. 2015;56(5):685-91. doi: 10.1111/epi.12984
18. Gilissen C, Hehir-Kwa JY, Thung DT, van de Vorst M, van Bon BW, Willemsen MH, et al. Genome sequencing identifies major causes of severe intellectual disability. *Nature*. 2014;511:344-7. doi: 10.1038/nature13394
19. Zhu X, Petrovski S, Xie P, Ruzzo EK, Lu YF, McSweeney KM, et al. Whole-exome sequencing in undiagnosed genetic diseases: interpreting 119 trios. *Genet Med*. 2015;17(10):774-81. doi: 10.1038/gim.2014.191
20. Richards S, Aziz N, Bale S, Bick D, Das S, Gastier-Foster J, et al. Standards and guidelines for the interpretation of sequence variants: a joint consensus recommendation of the American College of Medical Genetics and Genomics and the Association for Molecular Pathology. *Genet Med*. 2015;17(5):405-24. doi: 10.1038/gim.2015.30
21. Sun Y, Ruivenkamp CA, Hoffer MJ, Vrijenhoek T, Kriek M, van Asperen CJ, et al. Next-generation diagnostics: gene panel, exome, or whole genome? *Hum Mutat*. 2015;36(6):648-55. doi: 10.1002/humu.22783
22. Stark Z, Tan TY, Chong B, Brett GR, Yap P, Walsh M, et al. A prospective evaluation of whole-exome sequencing as a first-tier molecular test in infants with suspected monogenic disorders. *Genet Med*. 2016;18(11):1090-6. doi: 10.1038/gim.2016.1
23. Slezak R, Smigiel R, Rydzanicz M, Pollak A, Kosinska J, Stawinski P, et al. Phenotypic expansion in Zhu-Tokita-Takenouchi-Kim syndrome caused by de novo variants in the SON gene. *Mol Genet Genomic Med* [Internet]. 2020[cited 2022 Nov 10];8(10):e1432. Available from: <https://onlinelibrary.wiley.com/doi/10.1002/mgg3.1432> doi: 10.1002/mgg3.1432
24. Kim JH, Shinde DN, Reijnders MRF, Hauser NS, Belmonte RL, Wilson GR, et al. De Novo Mutations in SON Disrupt RNA Splicing of Genes Essential for Brain Development and Metabolism, Causing an Intellectual-Disability Syndrome. *Am J Hum Genet*. 2016;99(3):711-9. doi: 10.1016/j.ajhg.2016.06.029
25. Tokita MJ, Braxton AA, Shao Y, Lewis AM, Vincent M, Kury S, et al. De Novo Truncating Variants in SON Cause Intellectual Disability, Congenital Malformations, and Failure to Thrive. *Am J Hum Genet*. 2016;99(3):720-7. doi: 10.1016/j.ajhg.2016.06.035
26. Takenouchi T, Miura K, Uehara T, Mizuno S, Kosaki K. Establishing SON in 21q22.11 as a cause a new syndromic form of intellectual disability: Possible contribution to Braddock-Carey syndrome phenotype. *Am J Med Genet A*. 2016;170(10):2587-90. doi: 10.1002/ajmg.a.37761
27. Kim JH, Baddoo MC, Park EY, Stone JK, Park H, Butler TW, et al. SON and Its Alternatively Spliced Isoforms Control MLL Complex-Mediated H3K4me3 and Transcription of Leukemia-Associated Genes. *Mol Cell*. 2016;61(6):859-73. doi: 10.1016/j.molcel.2016.02.024
28. Yang Y, Xu L, Yu Z, Huang H, Yang L. Clinical and genetic analysis of ZTTK syndrome caused by SON heterozygous mutation c.394C>T. *Mol Genet Genomic Med* [Internet]. 2019[cited 2022 Nov 10];7(11):e953. Available from: <https://www.ncbi.nlm.nih.gov/pmc/articles/PMC6825855/pdf/MGG3-7-e953.pdf> doi: 10.1002/mgg3.953
29. Kushary ST, Revah-Politi A, Barua S, Ganapathi M, Accogli A, Aggarwal V, et al. ZTTK syndrome: Clinical and molecular findings of 15 cases and a review of the literature. *Am J Med Genet A*. 2021;185(12):3740-53. doi: 10.1002/ajmg.a.62445
30. Castaneda LQ, Orta AS, Pedrero RM, Simarro FS, Bralo MP, Rodríguez MF, et al. Skin and nails abnormalities in a patient with ZTTK syndrome and a de novo mutation in SON. *Pediatr Dermatol*. 2020 ;37(3):517-9. doi: 10.1111/pde.14113
31. Ueda M, Matsuki T, Fukada M, Eda S, Toya A, Iio A, et al. Knockdown of Son, a mouse homologue of the ZTTK syndrome gene, causes neuronal migration defects and dendritic spine abnormalities. *Mol Brain* [Internet]. 2020[cited 2022 Nov 11];13(1):80. Available from: <https://molecularbrain.biomedcentral.com/articles/10.1186/s13041-020-00622-4> doi: 10.1186/s13041-020-00622-4
32. Ahn EEE, Higashi T, Yan M, Matsuura S, Hickey CJ, Lo MC, et al. SON protein regulates GATA-2 through transcriptional control of the microRNA 23a~27a~24-2 cluster. *J Biol Chem*. 2013;288(8):5381-8. doi: 10.1074/jbc.M112.447227
33. Kim JH, Park EY, Chitayat D, Stachura DL, Schaper J, Lindstrom K, et al. SON haploinsufficiency causes impaired pre-mRNA splicing of CAKUT genes and heterogeneous renal phenotypes. *Kidney Int*. 2019;95(6):1494-1504. doi: 10.1016/j.kint.2019.01.025
34. Chiu C, Loth S, Kuhlén M, Ginzler S, Schaper J, Rosenbaum T, et al. Mutated SON putatively causes a cancer syndrome comprising high-risk medulloblastoma combined with café-au-lait spots. *Fam Cancer*. 2019;18(3):353-8. doi: 10.1007/s10689-019-00121-z
35. Vukadin L, Kim JH, Hackwelder TB, Ungerleider N, Flemington E, Ahn, EYE. Hematological Disorders in Human Patients with Son Mutations. *Blood* [Internet]. 2019[cited 2022 Nov 11];134(1):3709. Available from: <https://www.sciencedirect.com/science/article/pii/S0006497118616374> doi: 10.1182/blood-2019-130616

ГЕНЕТИЧНІ ЕПІЛЕПТИЧНІ ТА РОЗВИТКОВІ ЕНЦЕФАЛОПАТІЇ РАНЬОГО ВІКУ: ВІД СИМПТОМІВ ДО ДІАГНОЗУ

Л.Г.Кирилова, О.О.Юзва, О.О.Мірошников, Н.Ю.Бондаренко, О.В.Берегела

ДУ «Інститут педіатрії, акушерства і гінекології імені академіка О.М. Лук'янової НАМН України»
(м. Київ, Україна)

Резюме

Вступ. Проблема ранньої діагностики орфанних (рідкісних або раритетних) захворювань є актуальною для більшості країн світу. Викликом для медицини є попередження нових випадків орфанних захворювань шляхом медико-генетичного консультування на етапі планування сім'ї. Відділення психоневрології ДУ «Інститут педіатрії, акушерства і гінекології імені академіка О.М. Лук'янової НАМН України» займається проблемою орфанних захворювань з 2012 року і має значний досвід їх діагностики та лікування у дітей.

Мета роботи: розробити алгоритм генетичної діагностики епілептичних та розвиткових енцефалопатій дітей із затримкою розвитку та стигмами дизембріогенезу на основі сучасних даних щодо застосування та інтерпретації методів генетичного дослідження. Навести приклад складності інтерпретації отриманих результатів та алгоритмів ранньої діагностики пацієнтів та важливість проведення медико-генетичного консультування на етапах планування сім'ї.

Матеріал та методи дослідження: загально-клінічний огляд та дослідження неврологічного статусу, відео-ЕЕГ моніторинг під час нічного сну, магнітно-резонансна томографія головного мозку (3,0Т), повноекзомне секвенування (WES).

Результати дослідження. У статті представлено алгоритм генетичної діагностики орфанних захворювань у дітей, що супроводжуються епілептичними енцефалопатіями, затримкою розвитку та синдромом дисморфізму. Наведено приклад клінічного випадку хлопчика із загальною затримкою розвитку та атонічними епілептичними припадками.

При проведенні ЕЕГ-моніторингу нічного сну було виявлено епілептиформну активність у стадії повільного сну, що локалізувалася у центральній-тім'яній та лівій скроневій ділянках у вигляді доброякісних епілептиформних патернів дитинства.

При проведенні повноекзомного секвенування виявлено варіант нуклеотидної послідовності с.5887C>T (p.Arg1963Cys), у гені SON (англ. SON DNA binding protein) в гетерозиготному стані, який призводить до заміни аргініну на цистеїн. Мутації в гені SON в гетерозиготному стані описані у пацієнтів із синдромом Чжу-Токіта-Такенучі-Кім (OMIM: 617140) раніше були представлені у базі даних ClinVar як варіант невизначеного значення (VUS – variant of uncertain significance).

Висновки: Важливо, щоб спеціаліст у галузі педіатрії був обізнаний стосовно виявлення орфанних захворювань. Генетичні дослідження доступні і відкривають нові можливості діагностики, але потребують фахової клінічної лікарської інтерпретації. Після отримання результатів важливим є співставлення отриманих даних і клінічних ознак описаного синдрому. Тільки при відповідності клінічних проявів та результатів генетичного дослідження (наприклад, VUS) ми можемо стверджувати, що саме дана мутація є етіологічним фактором захворювання. У нашому випадку клінічні ознаки співпадали з даними, описаними авторами у 2015 році щодо першого випадку синдрому Чжу-Токіта-Такенучі-Кім, - таким чином, проведене генетичне дослідження допомогло верифікувати остаточний діагноз. Медико-генетичне консультування родин дозволяє проводити профілактику поширення орфанних захворювань в популяції.

Ключові слова: синдром Чжу-Токіта-Такенучі-Кім; розлад аутистичного спектру; епілепсія; повноекзомне секвенування; медико-генетичне консультування; планування сім'ї.

Contact Information:

Lyudmyla Kyrylova, MD, PhD, DSc, head of department of psychoneurology for children with perinatal lesions of nervous system and orphan diseases, SI «O.M. Lukyanova Institute of Pediatrics, Obstetrics and Gynecology NAMS of Ukraine» (Kyiv, Ukraine), President of the All-Ukrainian Public Organization «Association of Pediatric Neurologist of Ukraine».

e-mail: kirilova.lgr@gmail.com

ORCID ID: <https://orcid.org/0000-0002-9879-1132>

Scopus Author ID: <https://www.scopus.com/authid/detail.uri?authorId=57223344153>

Oleksandr Yuzva, researcher in department of psychoneurology for children with perinatal lesions of nervous system and orphan diseases, SI «O.M. Lukyanova Institute of Pediatrics, Obstetrics and Gynecology NAMS of Ukraine» (Kyiv, Ukraine)

e-mail: alexandermmu@gmail.com

ORCID ID: <https://orcid.org/0000-0002-0918-4788>

Scopus Author ID: <https://www.scopus.com/authid/detail.uri?authorId=57223343492>

Oleksandr Miroshnykov, PhD, scientific secretary of SI «O.M. Lukyanova Institute of Pediatrics, Obstetrics and Gynecology NAMS of Ukraine» (Kyiv, Ukraine)

e-mail: a.mirosh@ukr.net

ORCID ID: <https://orcid.org/0000-0002-7614-6335>

Scopus Author ID: <https://www.scopus.com/authid/detail.uri?authorId=57223339141>

Natalia Bondarenko, PhD, senior researcher in department of nutrition problems and somatic diseases in children, SI «O.M. Lukyanova Institute of Pediatrics, Obstetrics and Gynecology NAMS of Ukraine» (Kyiv, Ukraine)

e-mail: urabondarenko151@gmail.com

ORCID: <https://orcid.org/0000-002-7982-0970>

Olga Beregela, pediatric neurologist in department of psychoneurology for children with perinatal lesions of nervous system, SI «O.M. Lukyanova Institute of Pediatrics, Obstetrics and Gynecology NAMS of Ukraine» (Kyiv, Ukraine)

e-mail: beregela.ola@ukr.net

ORCID: <https://orcid.org/0000-0002-3040-698X>

Контактна інформація:

Кирилова Людмила Григорівна, д.мед.н., завідувач відділення психоневрології для дітей з перинатальною патологією та орфанними захворюваннями ДУ «Інститут педіатрії, акушерства і гінекології імені академіка О.М. Лук'янової НАМН України» (Київ, Україна), Президент Всеукраїнської Громадської організації «Асоціація дитячих неврологів України».

e-mail: kirilova.lgr@gmail.com

ORCID ID: <https://orcid.org/0000-0002-9879-1132>

Scopus Author ID: <https://www.scopus.com/authid/detail.uri?authorId=57223344153>

Юзва Олександр Олександрович – к.мед.н., науковий співробітник відділення психоневрології для дітей з перинатальною патологією та орфанними захворюваннями ДУ «Інститут педіатрії, акушерства і гінекології імені академіка О.М. Лук'янової НАМН України» (Київ, Україна).

e-mail: alexandermmu@gmail.com

ORCID ID: <https://orcid.org/0000-0002-0918-4788>

Scopus Author ID: <https://www.scopus.com/authid/detail.uri?authorId=57223343492>

Мірошников Олександр Олександрович - к.мед.н., учений секретар ДУ «Інститут педіатрії, акушерства і гінекології імені академіка О.М. Лук'янової НАМН України» (Київ, Україна).

e-mail: a.mirosh@ukr.net

ORCID ID: <https://orcid.org/0000-0002-7614-6335>

Scopus Author ID: <https://www.scopus.com/authid/detail.uri?authorId=57223339141>

Бондаренко Наталія Юріївна – к.мед.н., старший науковий співробітник відділення проблем харчування та соматичних захворювань ДУ «Інститут педіатрії, акушерства і гінекології імені академіка О.М. Лук'янової НАМН України» (Київ, Україна).

e-mail: urabondarenko151@gmail.com

ORCID: <https://orcid.org/0000-002-7982-0970>

Берегела Ольга Василівна – лікар невролог дитячий відділення психоневрології для дітей з перинатальною патологією та орфанними захворюваннями ДУ «Інститут педіатрії, акушерства і гінекології імені академіка О.М. Лук'янової НАМН України» (Київ, Україна).

e-mail: beregela.ola@ukr.net

ORCID: <https://orcid.org/0000-0002-3040-698X>



Received for editorial office on 08/06/2022

Signed for printing on 17/02/2023